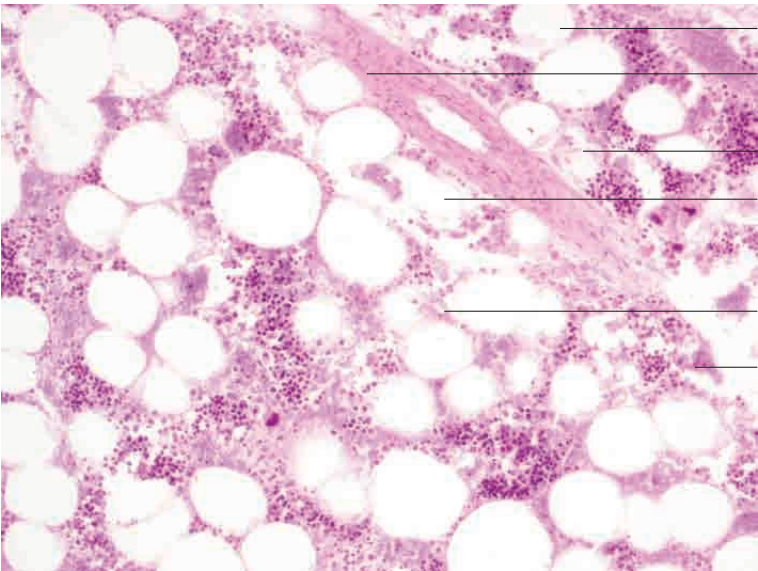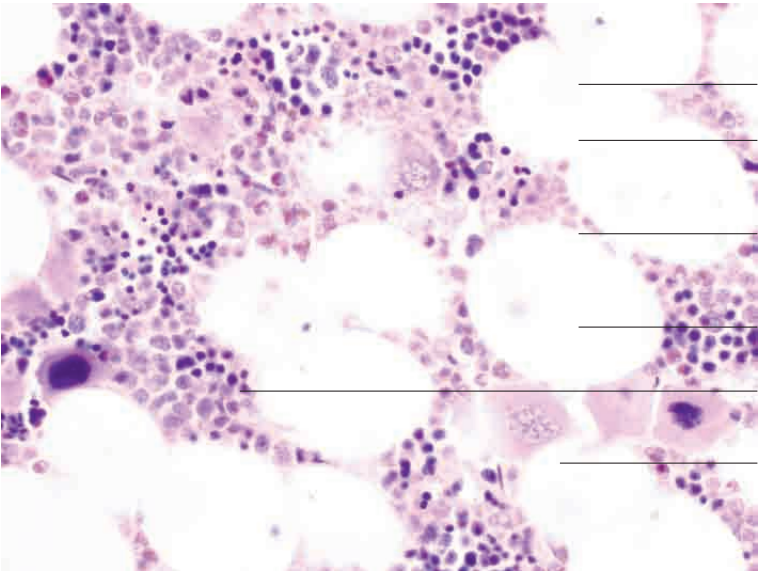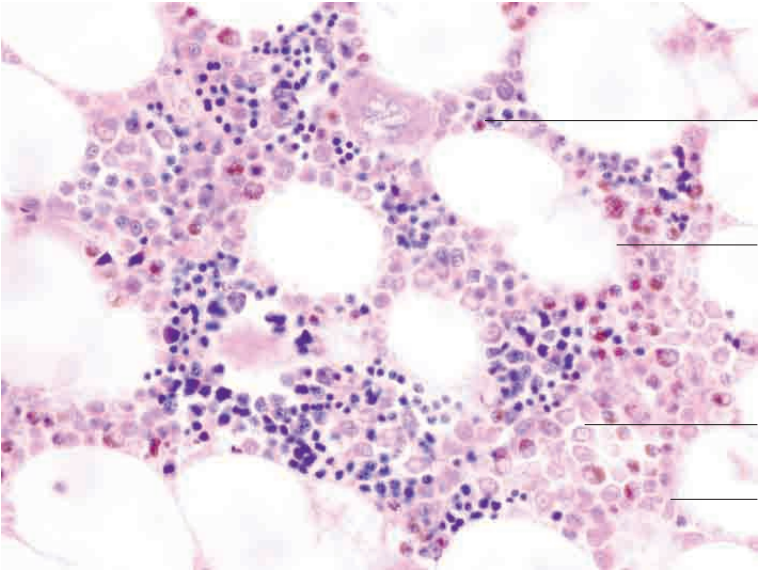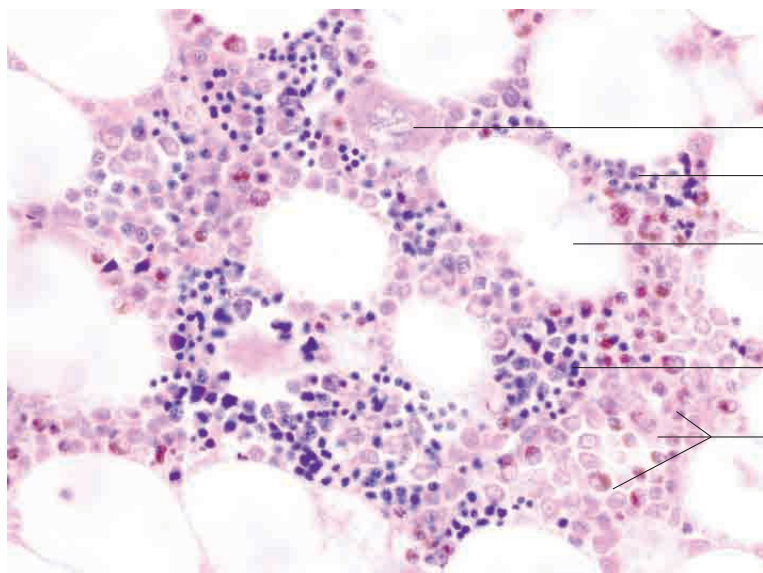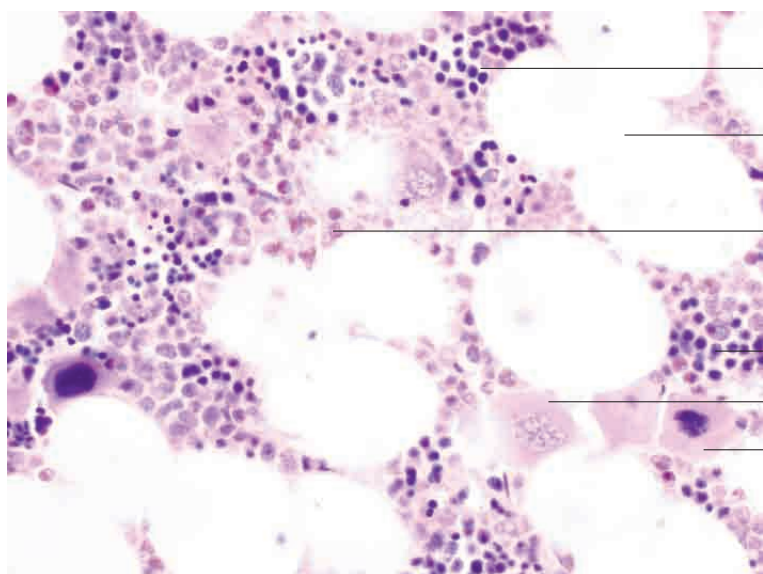


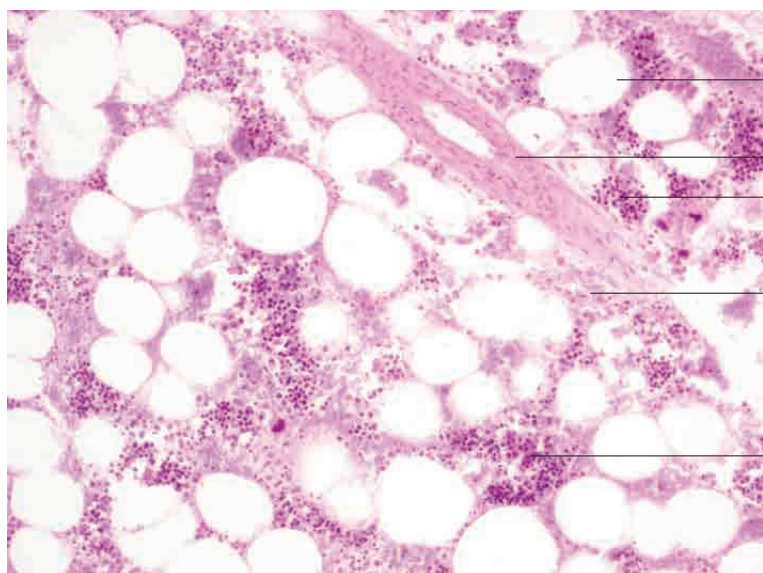
- Megakaryoblast
- Proerythroblasts/erythroblasts
- Adipocytes
- Proerythroblasts/Erythroblasts
- Differentiating cells of myeloid line

Bone marrow, ox. May-Grünwald stain; x480.



- Proerythroblasts/erythroblasts
- Adipocytes
- Cells of myeloid line in advanced stages of differentiation
- Proerythroblasts/erythroblasts
- Megakaryoblast
- Promegakaryocyte

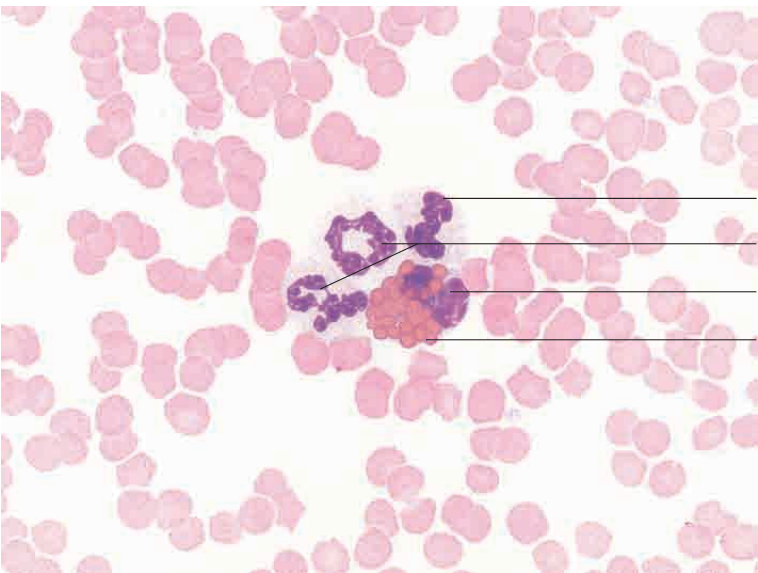
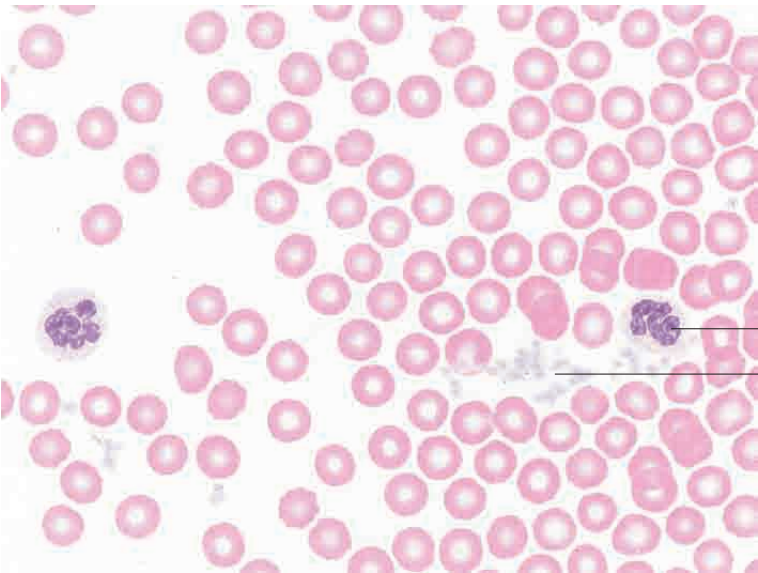
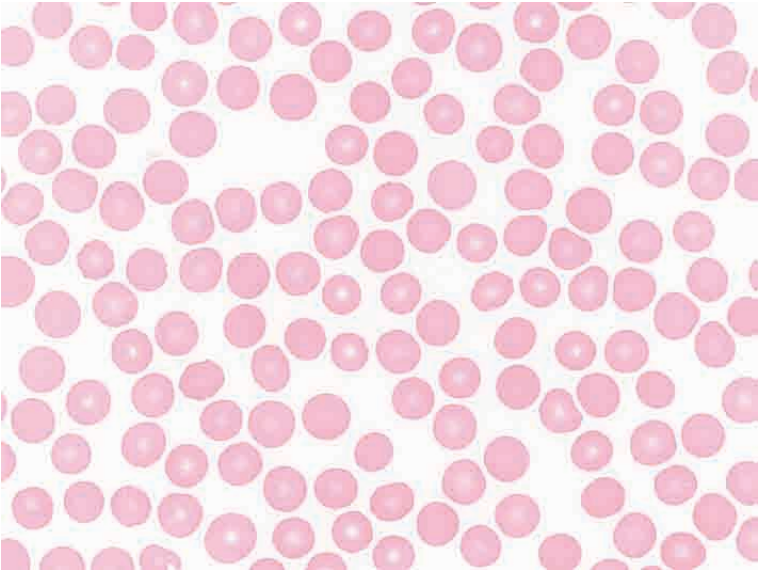
Bone marrow, ox. May-Grünwald stain; x480.

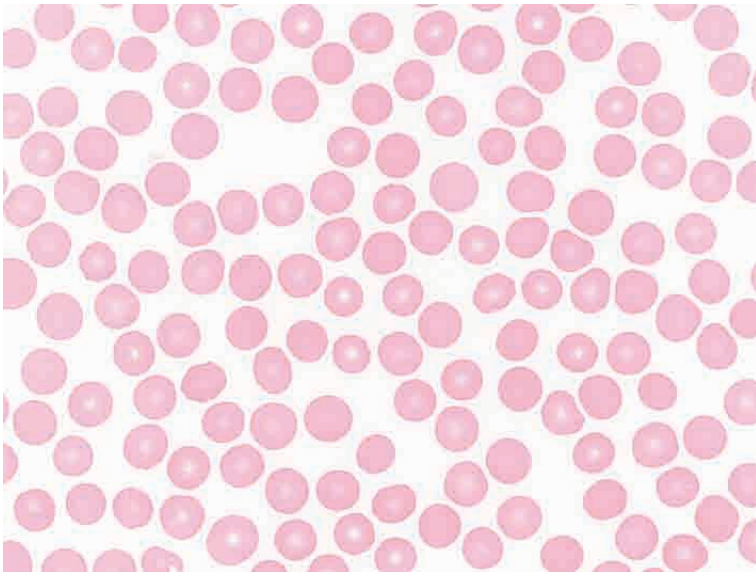


- Adipocytes
- Arteriole (oblique section)
- Proerythroblasts/erythroblasts
- Differentiating cells of myeloid line
- Proerythroblasts/erythroblasts

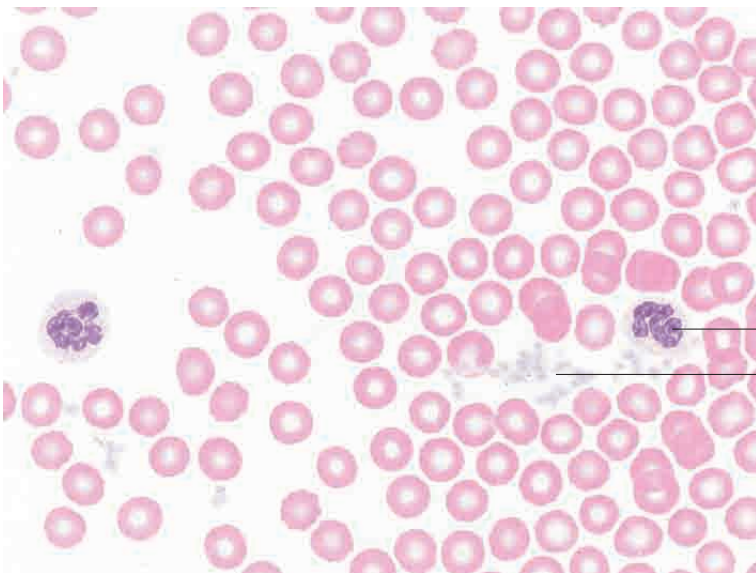
Bone marrow, horse. H.E. stain; x320.

7 Blood



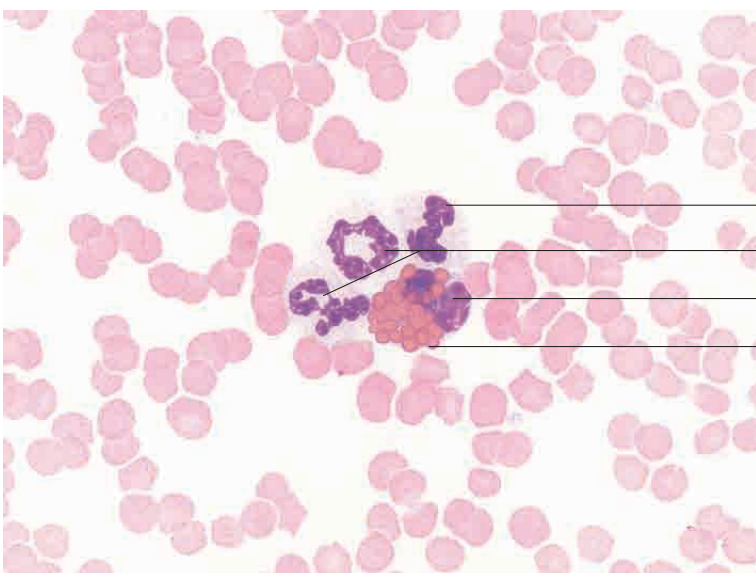


Blood smear, erythrocytes, horse.
Pappenheim stain; x1000.



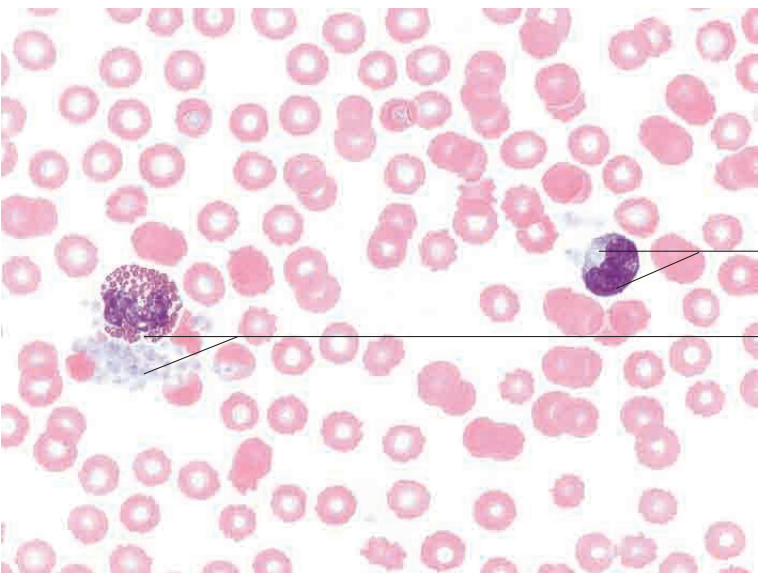
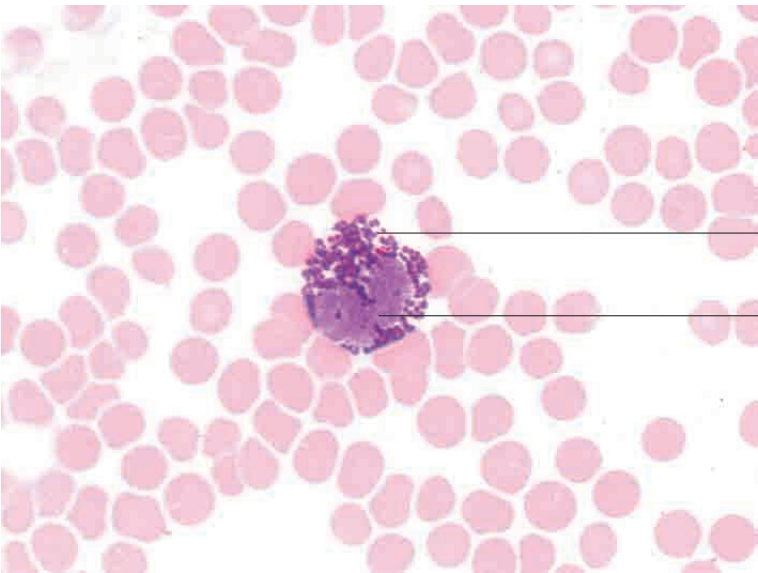
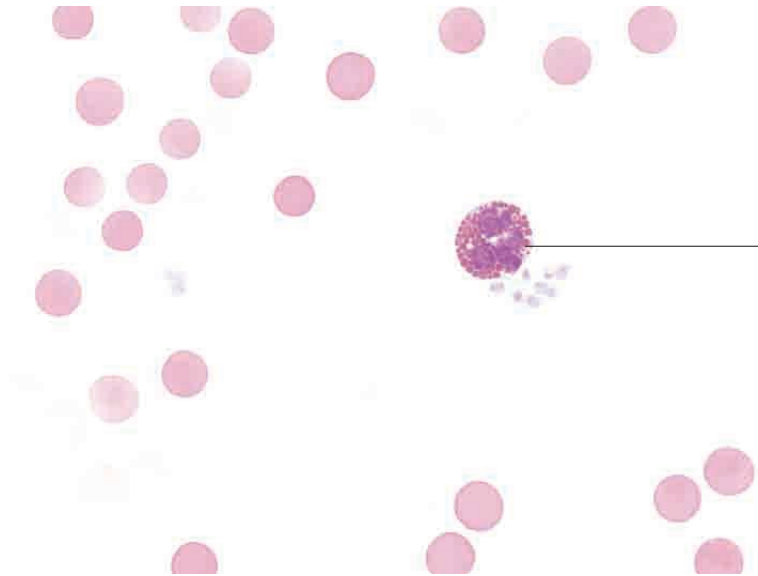
Segmented neutrophil
Thrombocytes

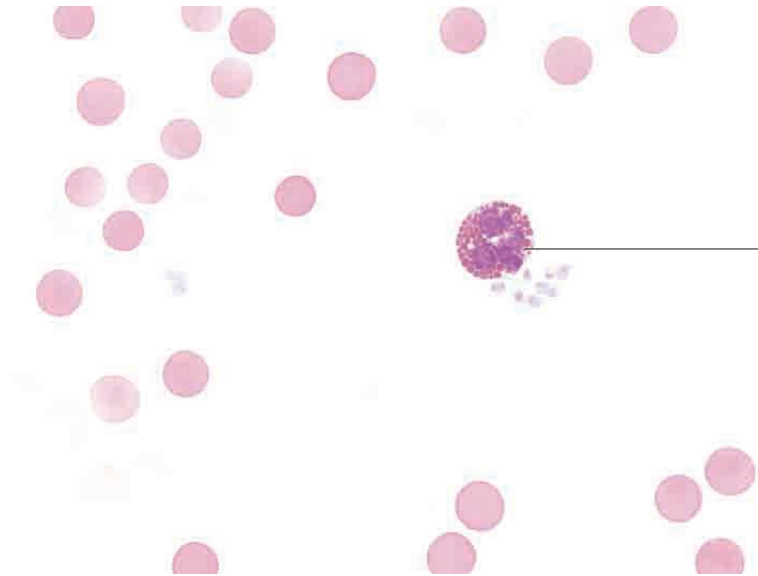
Blood smear, horse.
Pappenheim stain; x1000.



Band neutrophil
Segmented neutrophil
Segmented nucleus of eosinophil
Eosinophilic granules

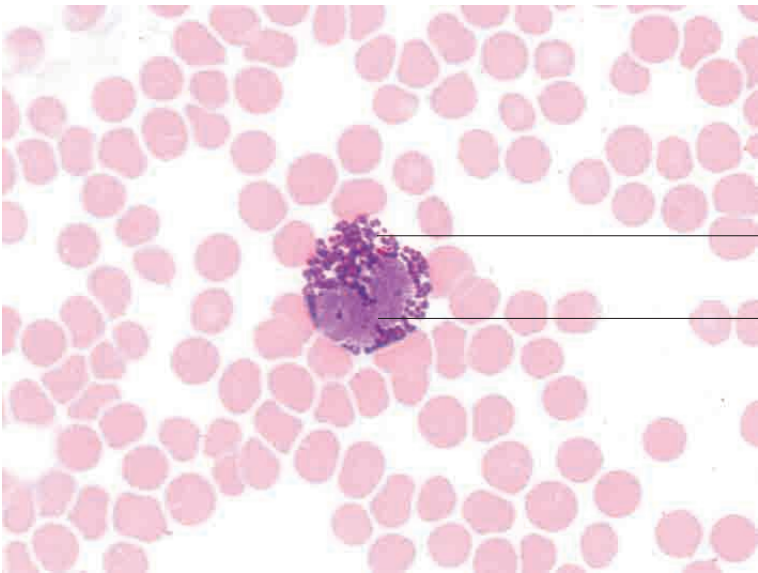
Blood smear, horse.
Pappenheim stain; x1000.





Eosinophil with prominent granules

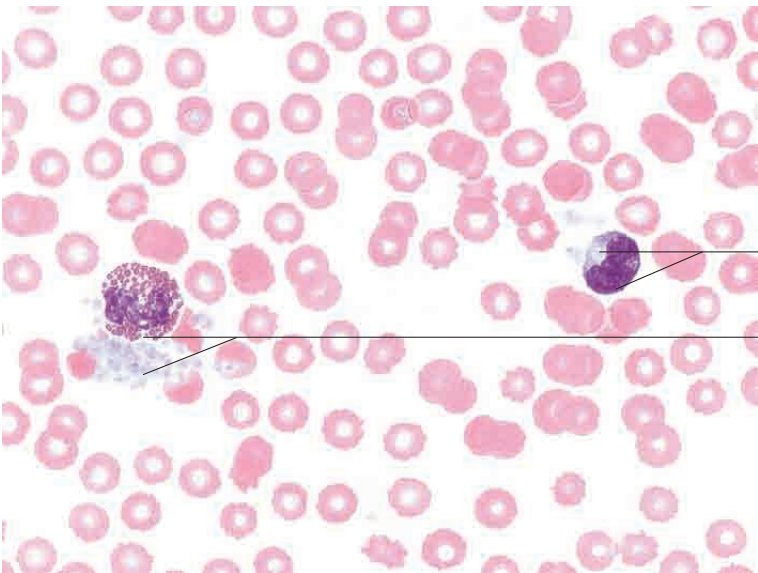
Blood smear, horse.
Pappenheim stain; x1000.



Basophil with prominent granules

Nucleus

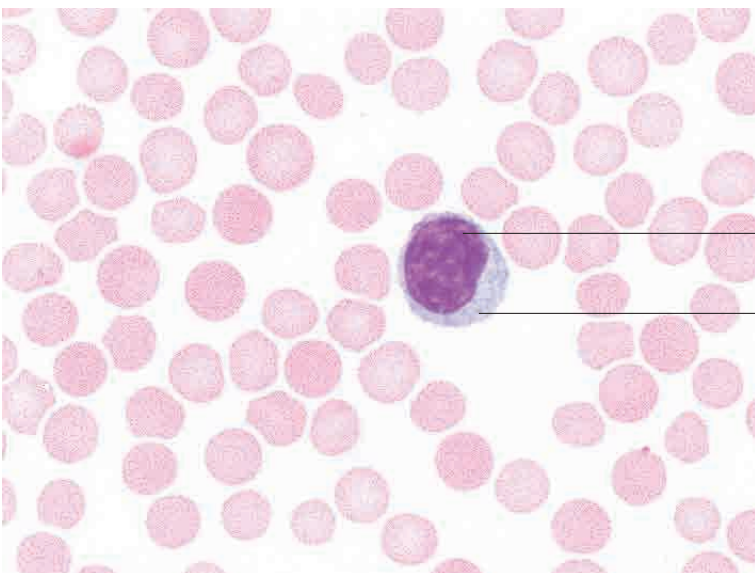
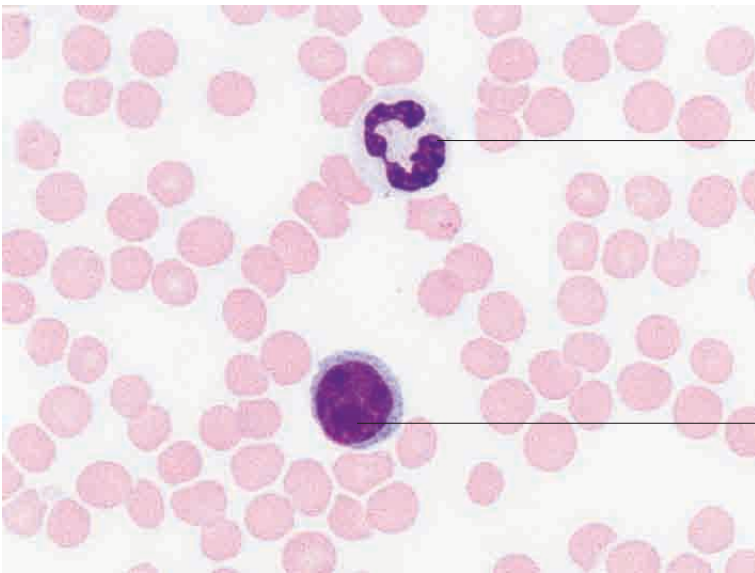
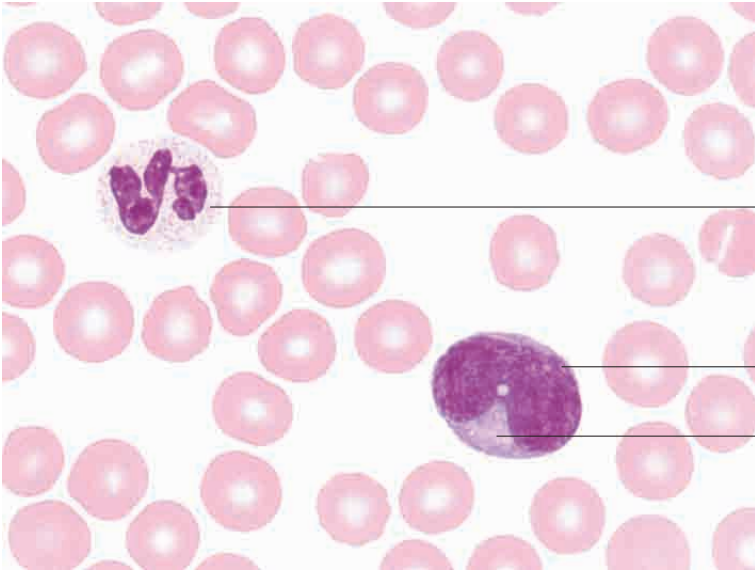
Blood smear, horse.
Pappenheim stain; x1000.

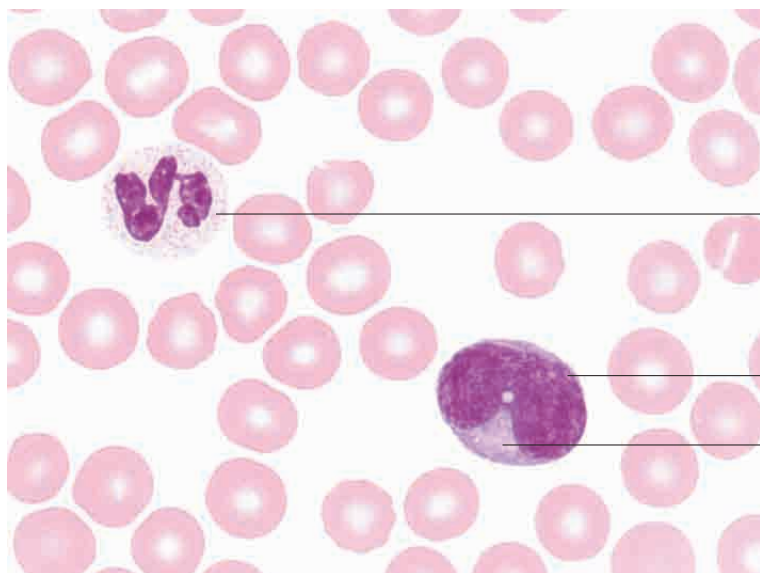


Pale cytoplasm and indented nucleus of monocyte

Eosinophils with adjacent thrombocytes

Blood smear, horse.
Pappenheim stain; x1000.



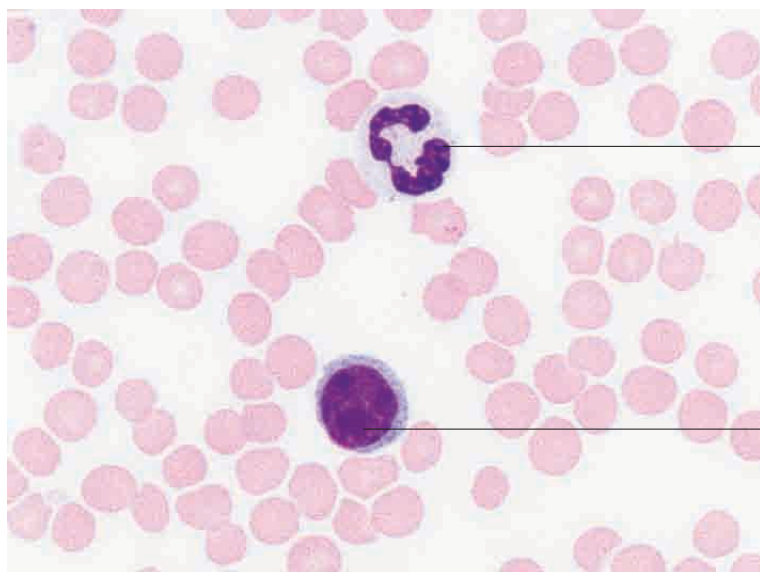


Segmented neutrophil with weakly staining granules

Bean-shaped nucleus of monocyte

Pale marginal cytoplasm

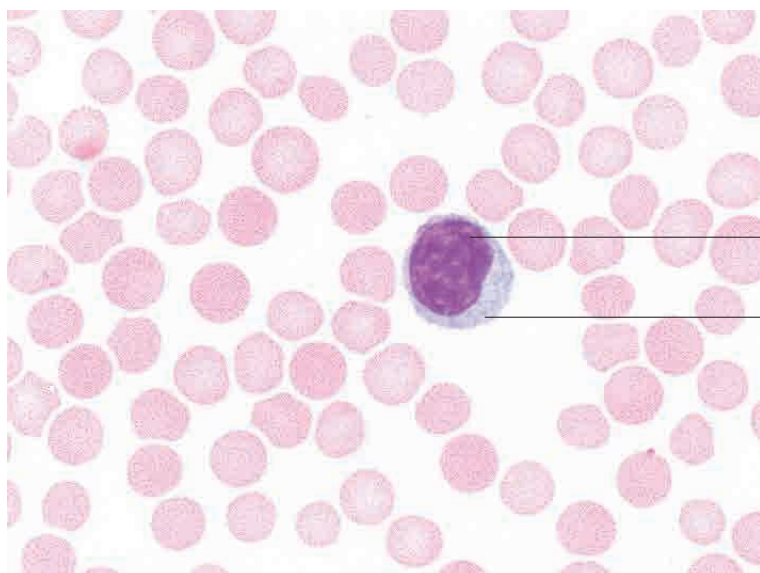
Blood smear, horse.
Pappenheim stain; x1200.



Segmented neutrophil with weakly staining granules

Small lymphocyte with narrow rim of cytoplasm

Blood smear, horse.
Pappenheim stain; x1000.

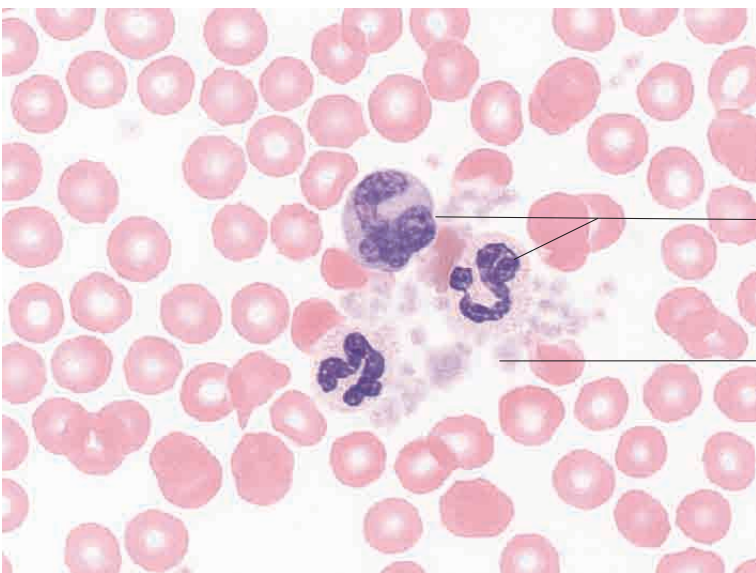
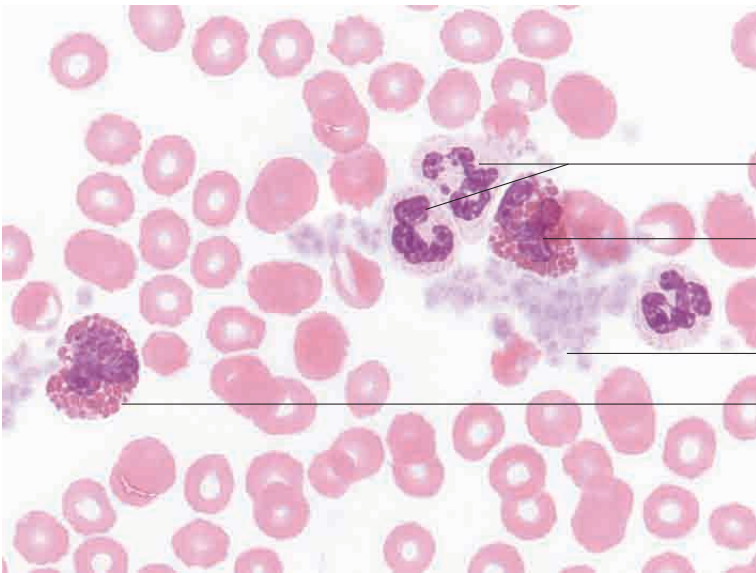
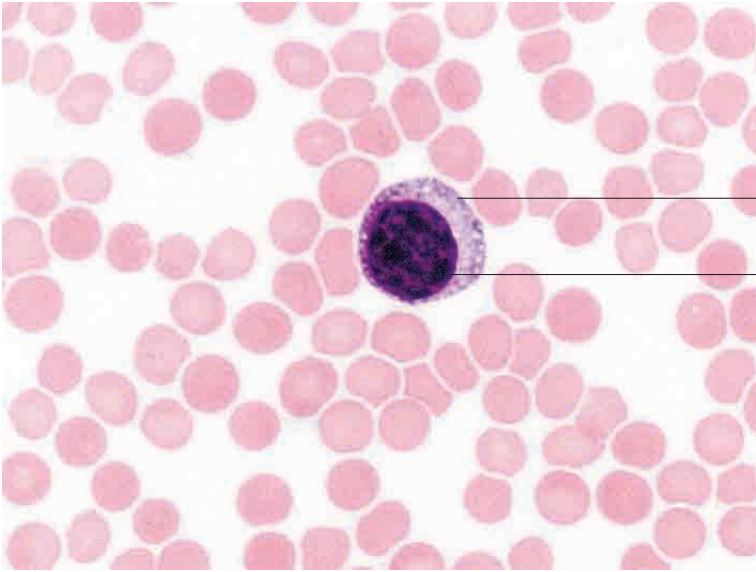


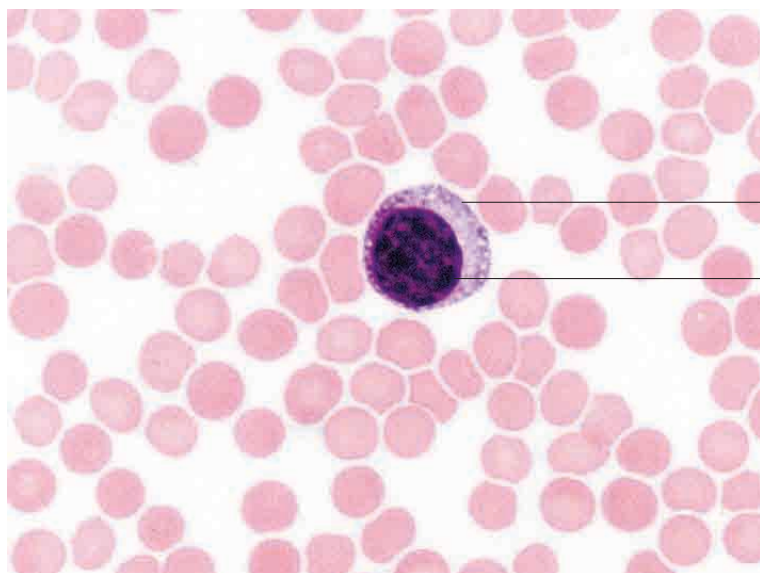
Dense, heterochromatic nucleus

Large lymphocyte with broad rim of cytoplasm

Blood smear, horse.
Pappenheim stain; x1200.

7 Blood

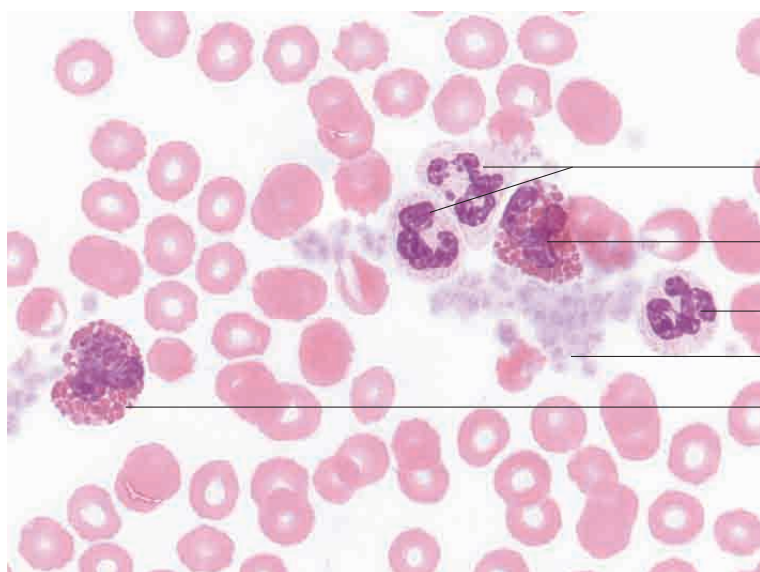




Large lymphocyte with broad rim of cytoplasm

Dense heterochromatic nucleus

Blood smear, horse.
Pappenheim stain; x1000.



Segmented neutrophil

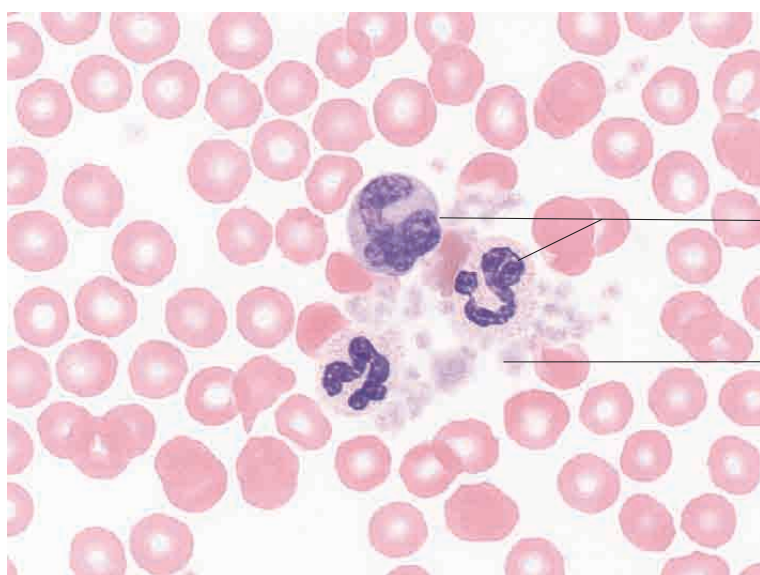
Eosinophil

Segmented neutrophil

Thrombocytes

Eosinophil

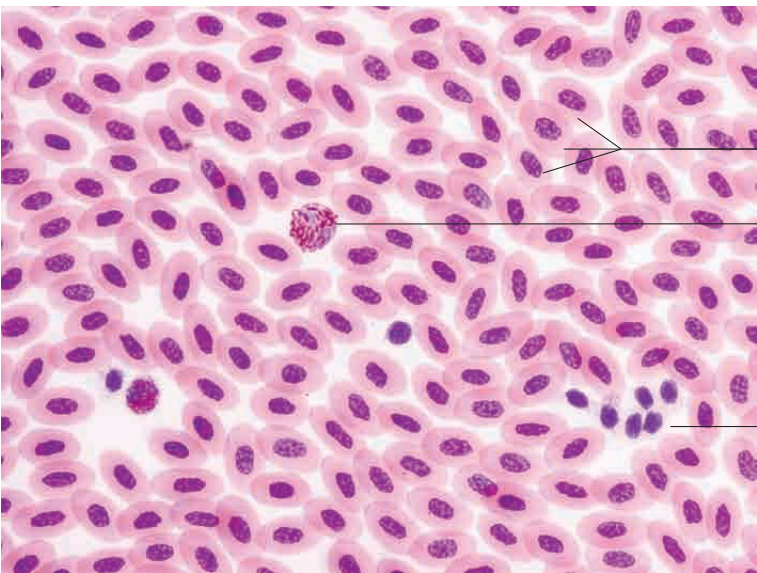
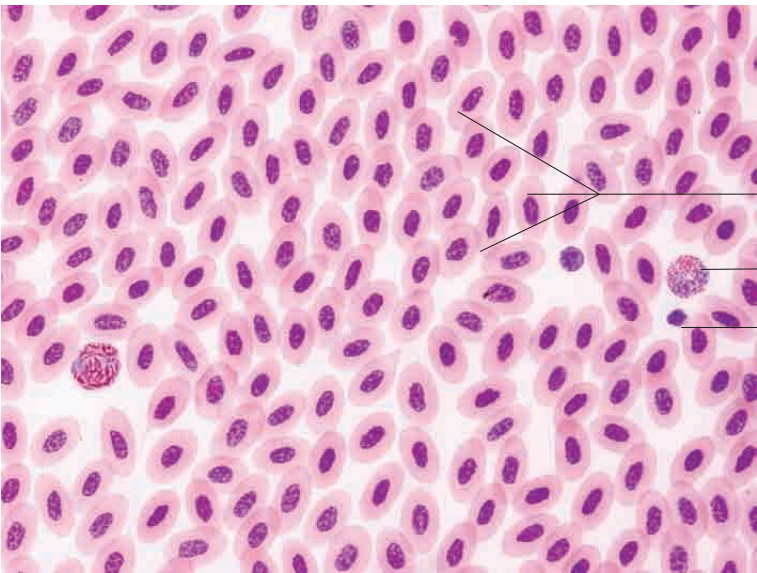
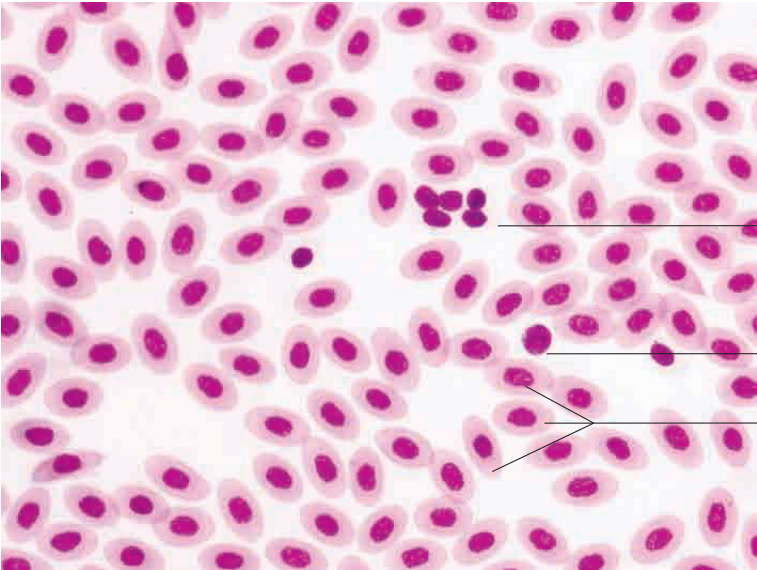
Blood smear, horse.
Pappenheim stain; x1000.

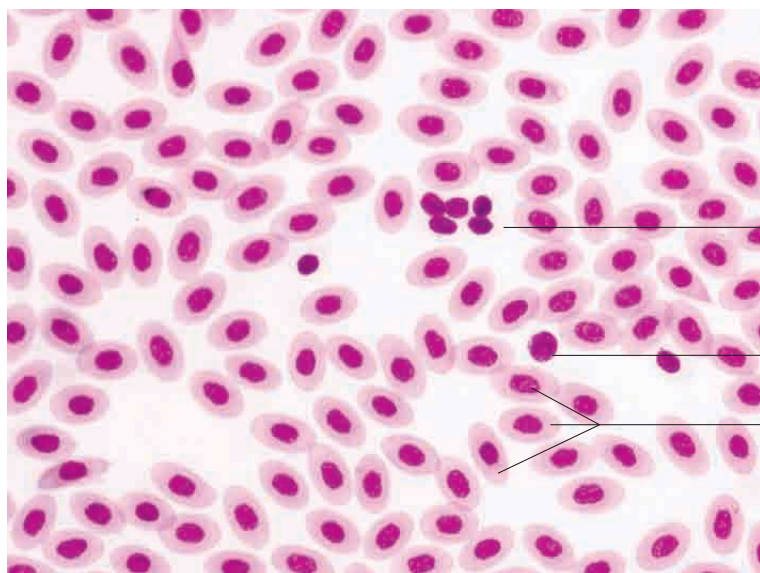


Segmented neutrophil with weakly staining granules

Thrombocytes

Blood smear, horse.
Pappenheim stain; x1000.



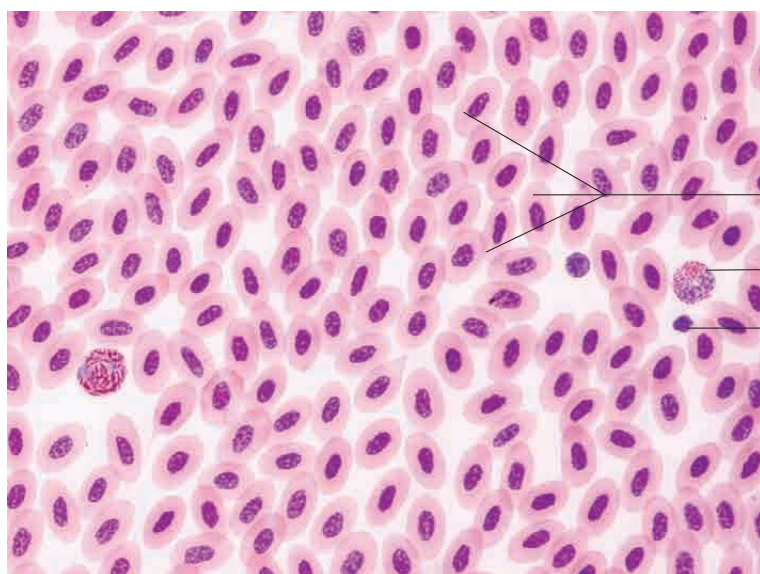


Spindle cells (avian thrombocytes)

Small lymphocyte

Nucleated erythrocytes

Blood smear, chicken.
Papanheim stain; x650.

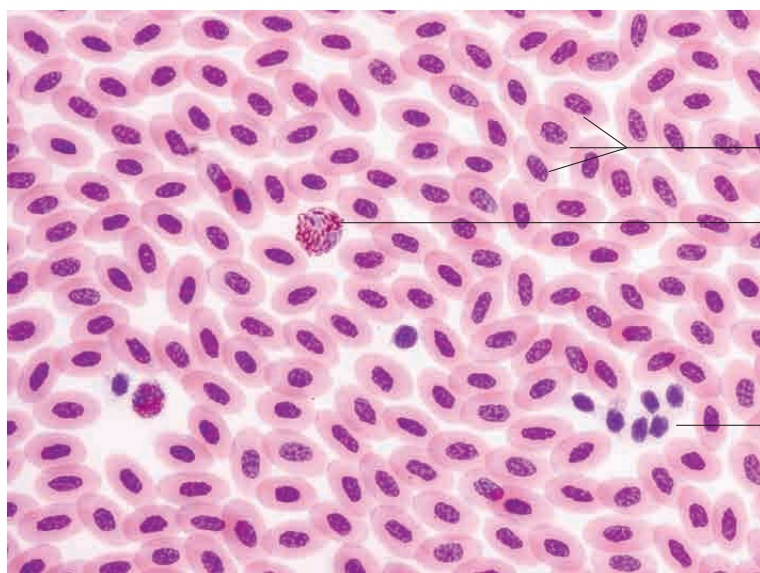


Nucleated erythrocytes

Eosinophil

Spindle cell (avian thrombocyte)

Blood smear, chicken.
Giemsa stain; x650.



Nucleated erythrocytes

Pseudoeosinophilic granulocyte

Spindle cells (avian thrombocytes)

Blood smear, chicken.
Giemsa stain; x650.