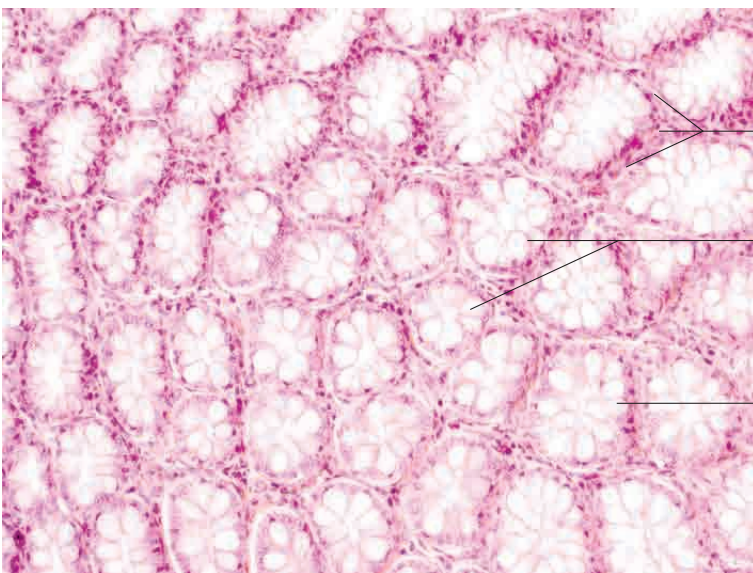
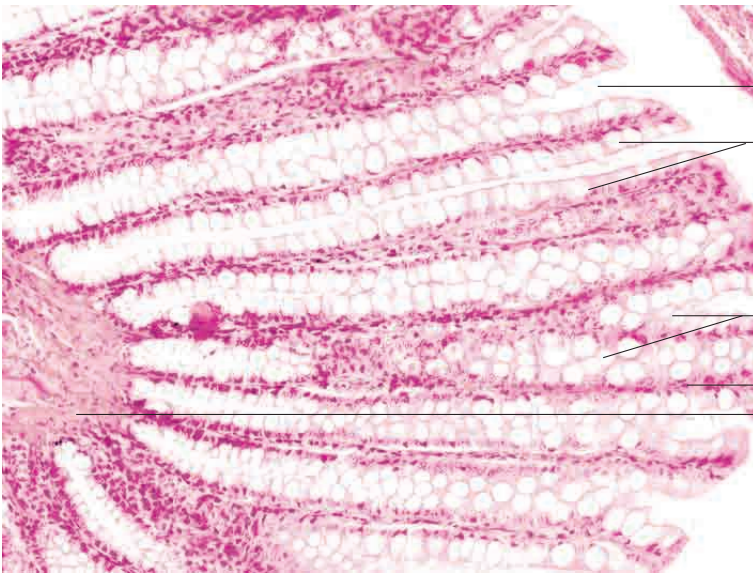
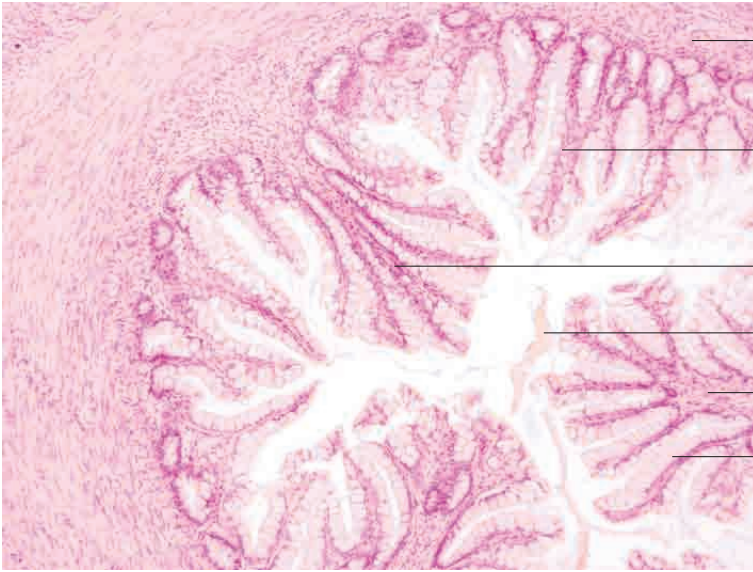
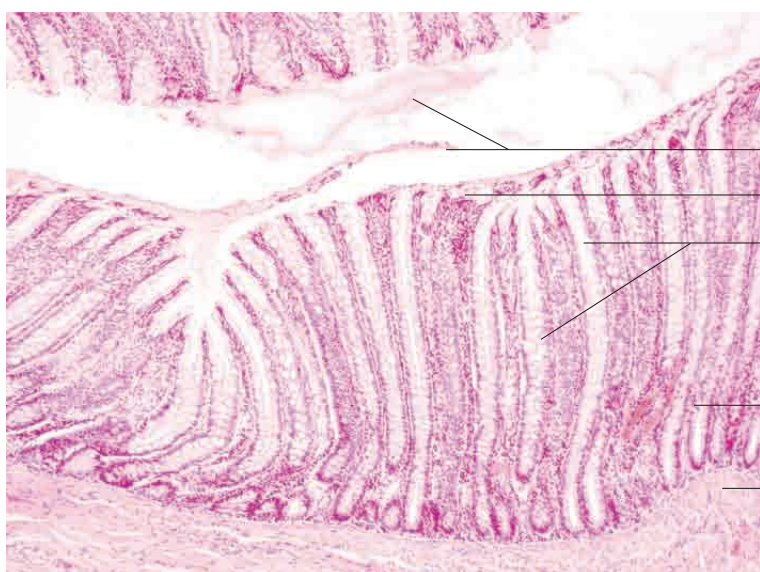
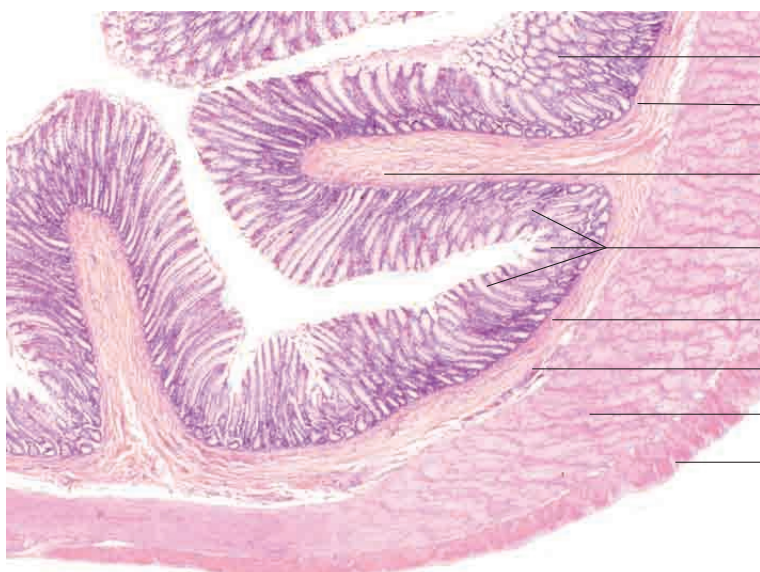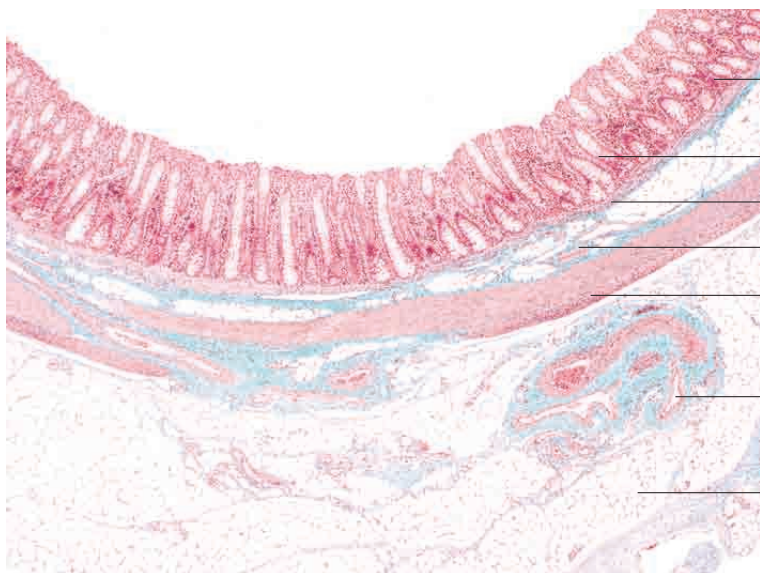
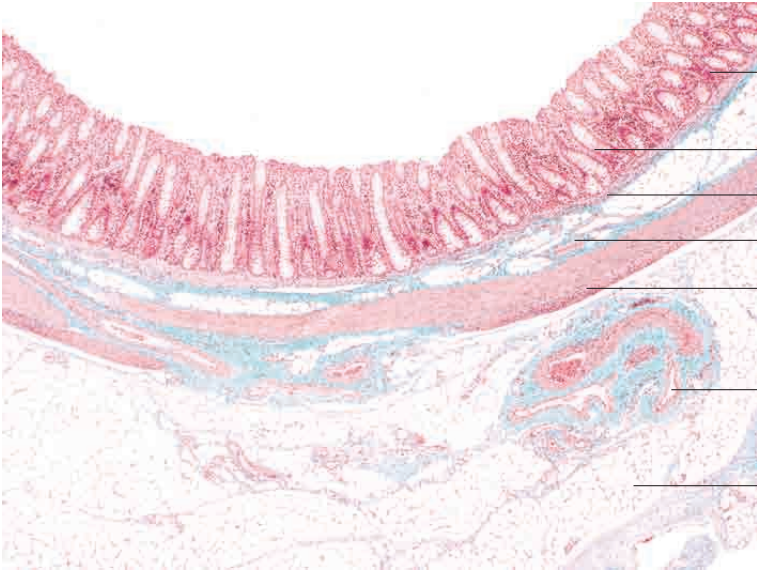


10 Digestive system



10 Digestive system



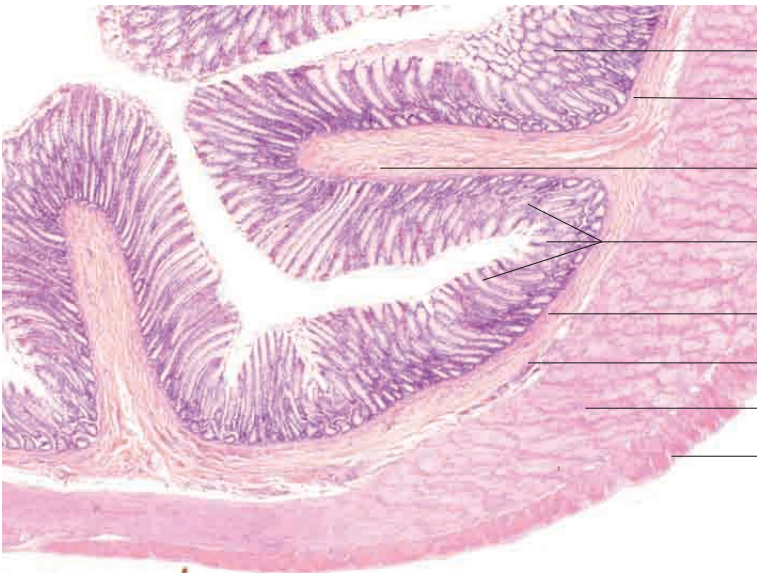


n o
 n n l l n
 mi m s m s s e
 e s m s
unica uscularis

arge arteries eins and autonomic ner e
 ibres in mesentery

Adipose tissu g

Eqnqp. {qwpi fqi 0 I qnfpgtju Ocuuqp vtkej tq o g
 uvckp= z620

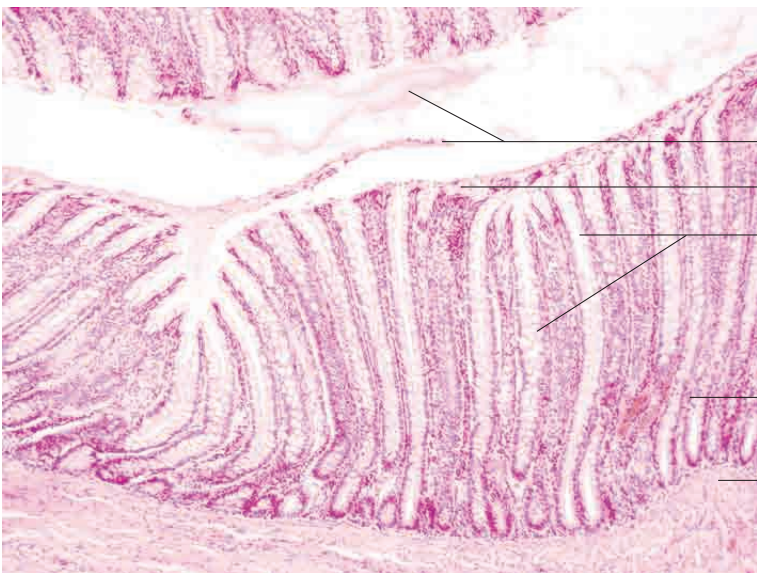

Vwpkcc o wequc *qdnkswg ugevkqp+
 Nc okpc owuewnctku owequcg

l o
 n n l l n

Nc okpc owuewnctku owequcg
 Vgnc uwd owequc
 Uvtcw o ektewnctg qh vwpkcc owuewnctku
 Uvtcw o nqpi kwf kpcng qh vwpkcc owuewnctku

g st 1 i



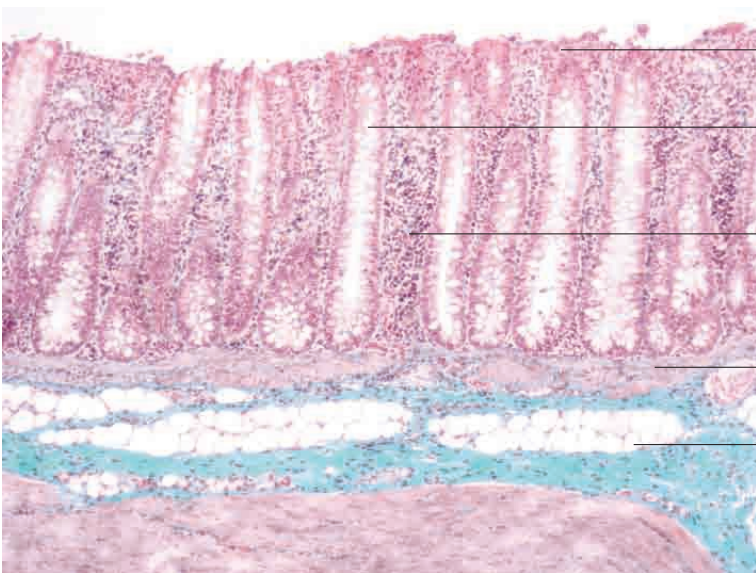
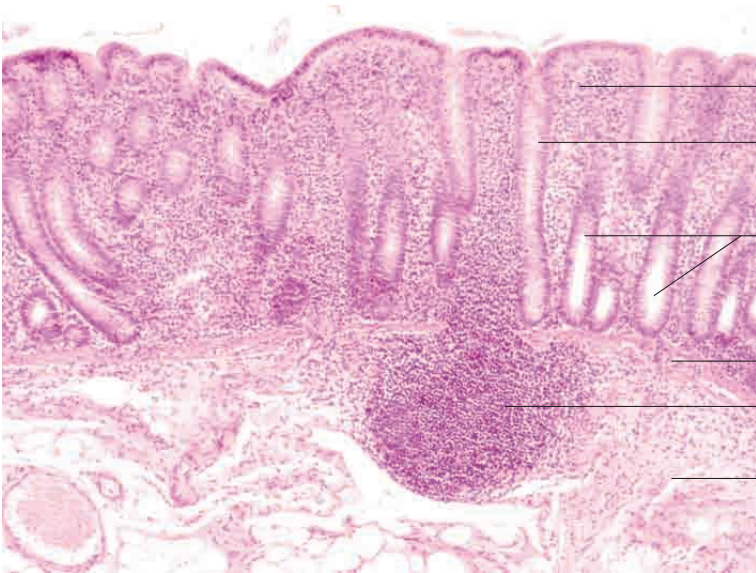
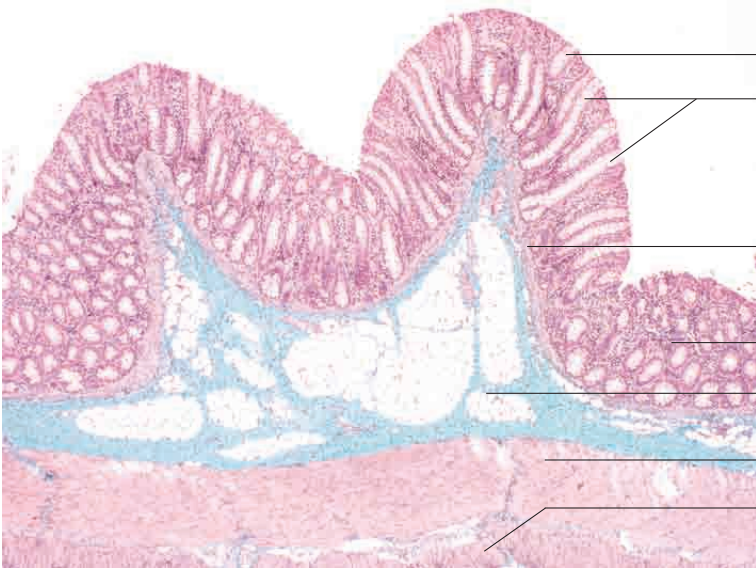Mucu n lu n
 ua a n p h l a l c ll
 n nal land h colu nar p h l
 and abundan obl c ll

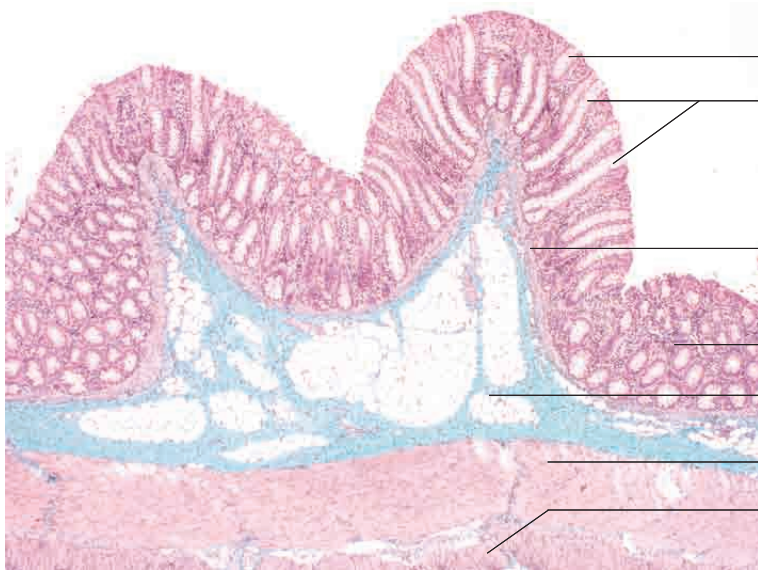mi m is e

mi m s m is s e

g st i 100

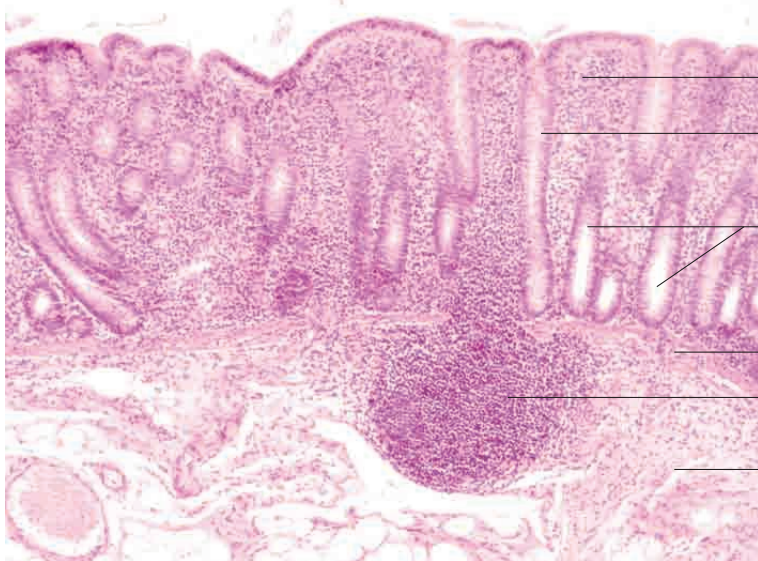
10 Digestive system





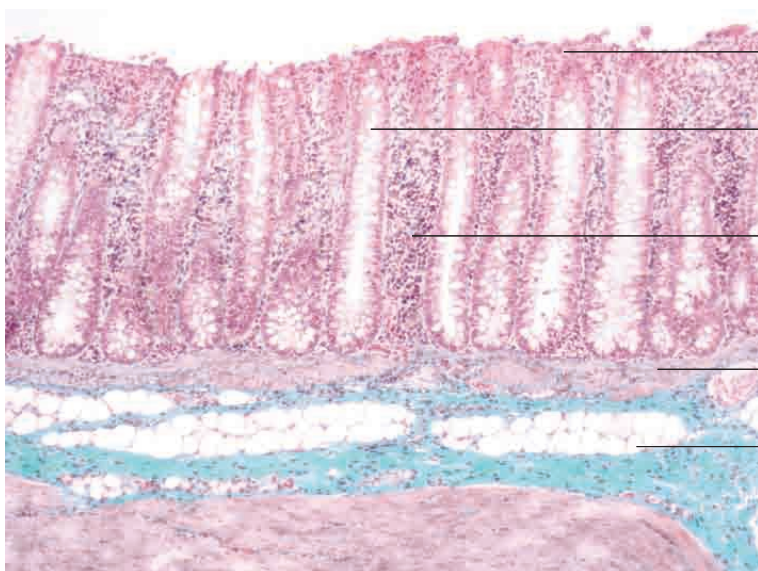
- Tunica mucosa (longitudinal section)
- Intestinal glands
- Lamina muscularis mucosae
- Tunica mucosa (oblique section)
- Tela submucosa
- Stratum circulare of tunica muscularis
- Stratum longitudinale of tunica muscularis

Colon, pig. Goldner's Masson trichrome stain; x40.



- Tunica mucosa (longitudinal section)
- Intestinal glands (longitudinal section)
- Intestinal glands (partial sections)
- Lamina muscularis mucosae
- Lymphoid follicle
- Tela submucosa

Colon, pig. H.E. stain; x100.



- Desquamating epithelial cells
- Intestinal glands
- with columnar epithelium and abundant goblet cells
- Lamina propria mucosae
- Lamina muscularis mucosae
- Tela submucosa

Colon, pig. Goldner,'s Masson trichrome stain; x100.