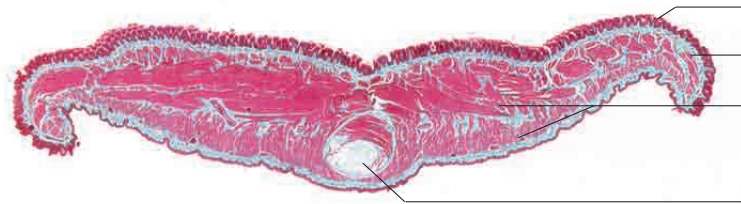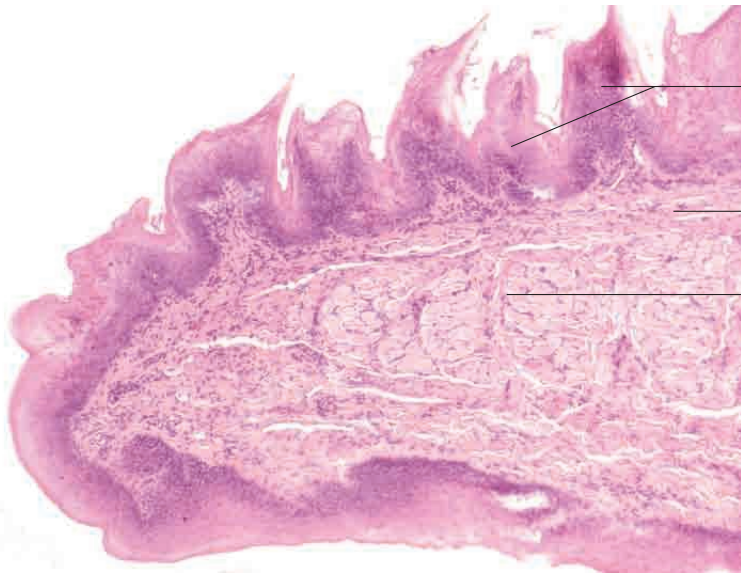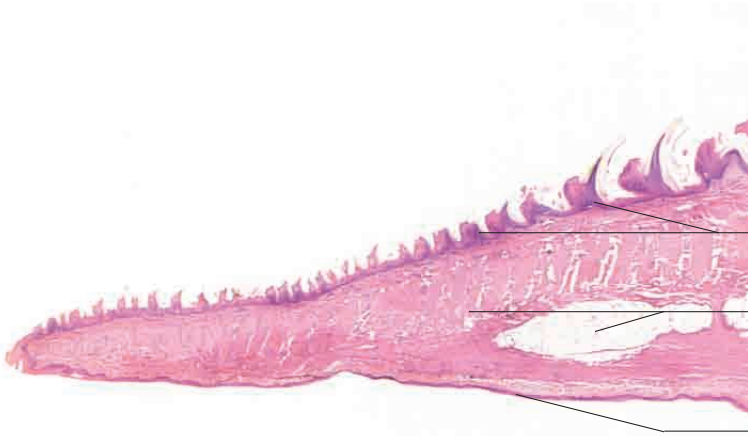


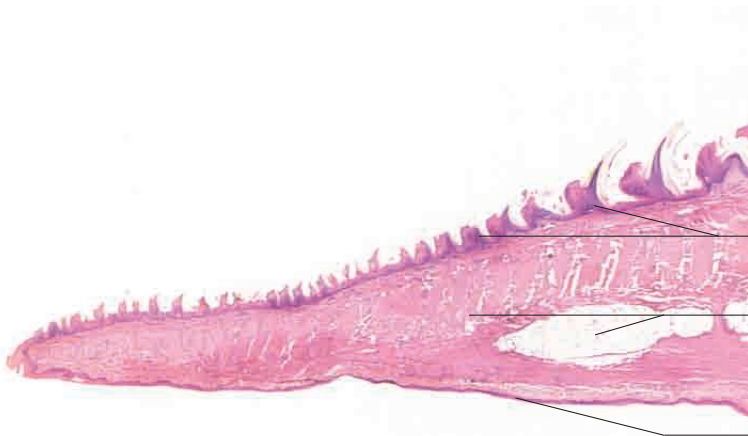# 10 Digestive system

---



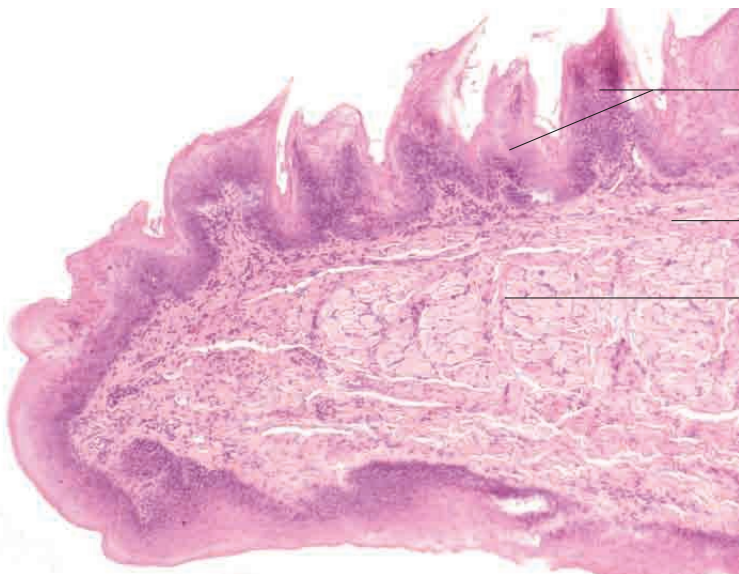


Stratified squamous epithelium with mechanical papillae (filiform papillae)

Intrinsic muscle of tongue (transverse, vertical and longitudinal fibres with fat bodies)

Ventral surface of tongue with weakly keratinised stratified squamous epithelium

Tongue, cat. H.E. stain; x10

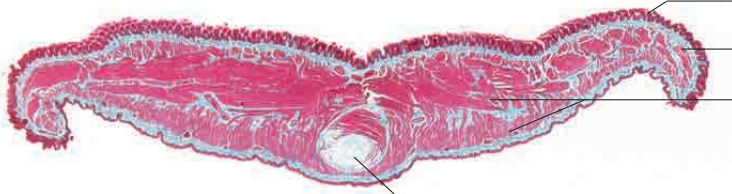

Stratified squamous epithelium with mechanical papillae (filiform papillae)

Lamina propria mucosae

Intrinsic muscle of tongue (transverse, vertical and longitudinal fibres)

Tip of tongue, cat. H.E. stain; x80.



Stratified squamous epithelium with mechanical papillae (filiform papillae)

Lamina propria mucosae

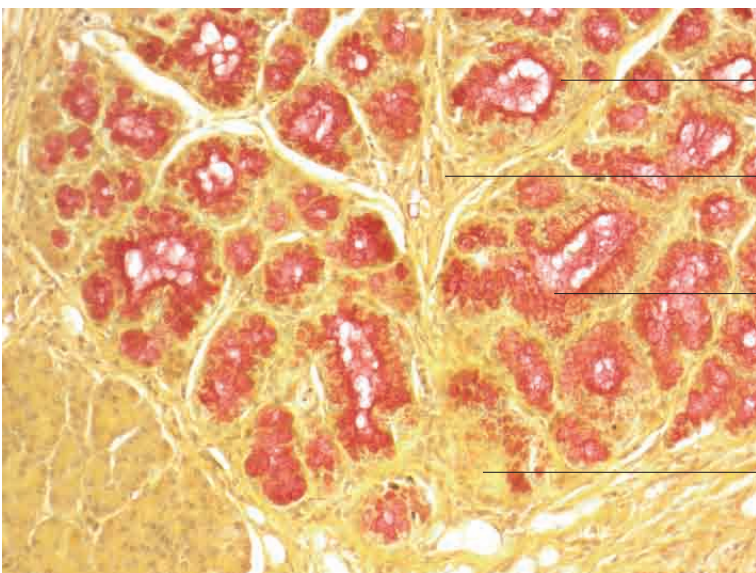
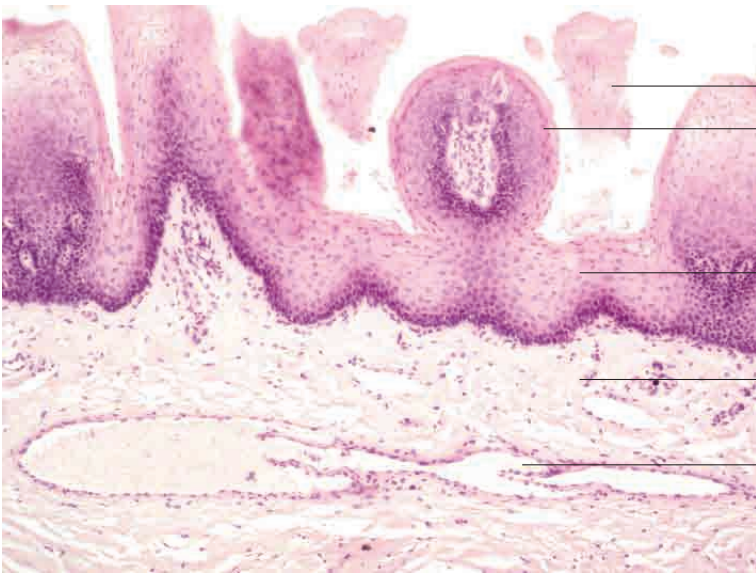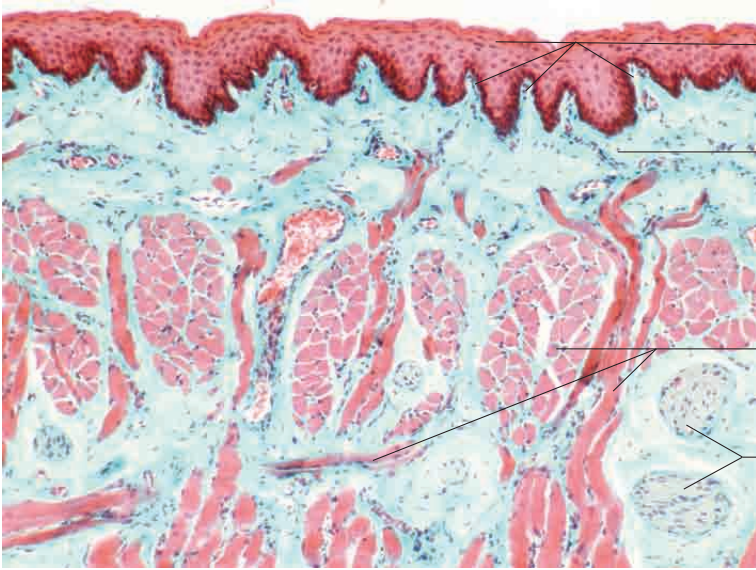
Intrinsic muscle of tongue (transverse, vertical and longitudinal fibres)

Lyssa

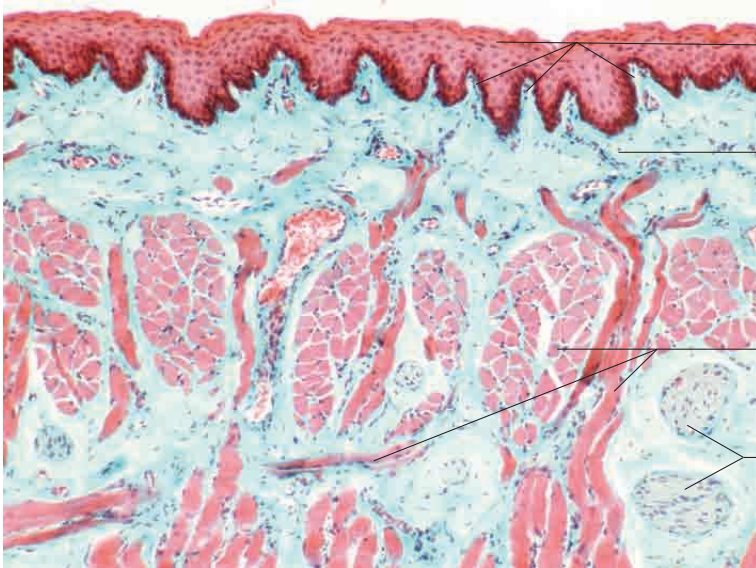
Tongue, dog. Goldner's Masson trichrome stain; x5.

# 10 Digestive system

---







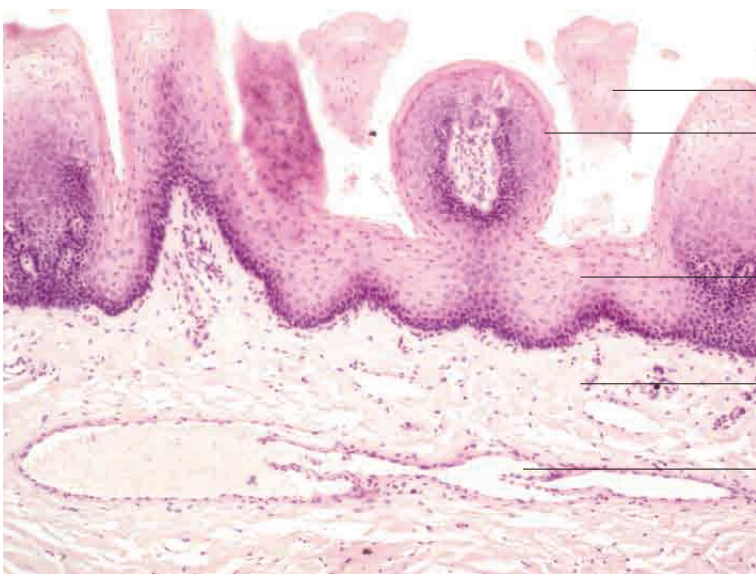
Stratified squamous epithelium with marked papillation

Lamina propria mucosae

Intrinsic muscle of tongue (transverse, vertical and longitudinal fibres)

Mixed nerve fibre bundle

Tongue, dog. Goldner's Masson trichrome stain; x40.



Lingual papilla (partial section)

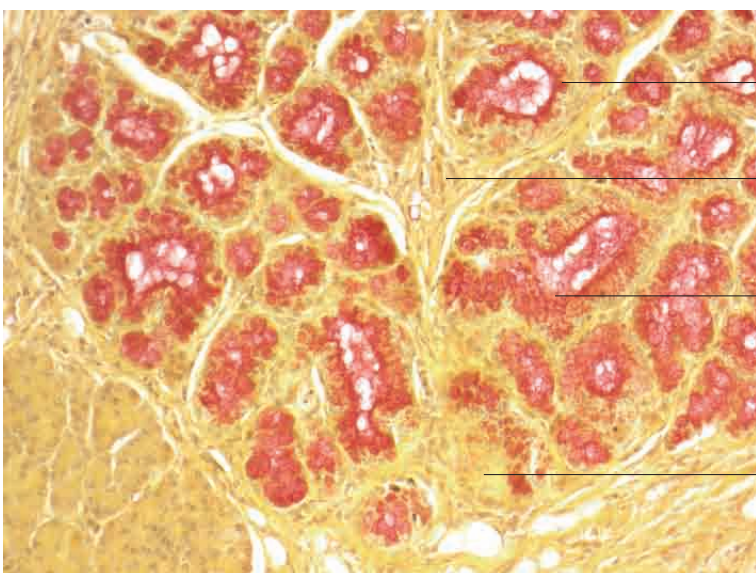
Filiform papilla

Stratified squamous epithelium

Lamina propria mucosae

Submucosal venous plexus with valve

Tongue, dog. H.E. stain; x120.



Actively secreting mixed glands

Prominent connective tissue producing lobulation

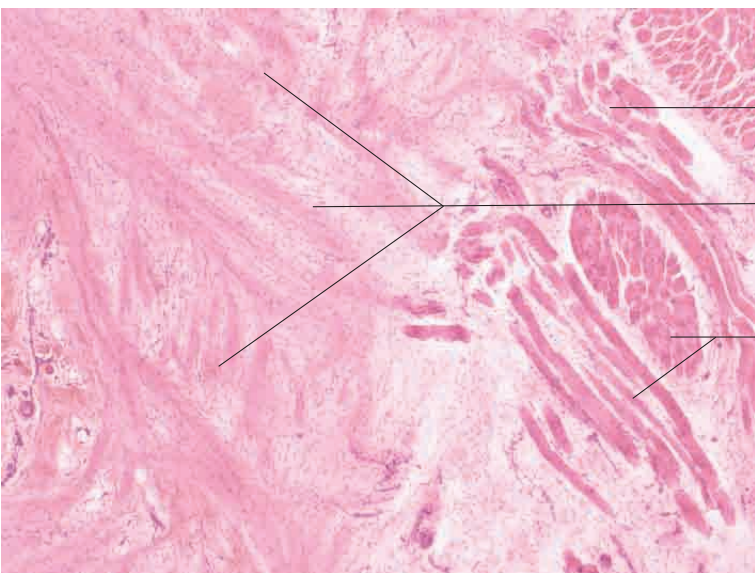
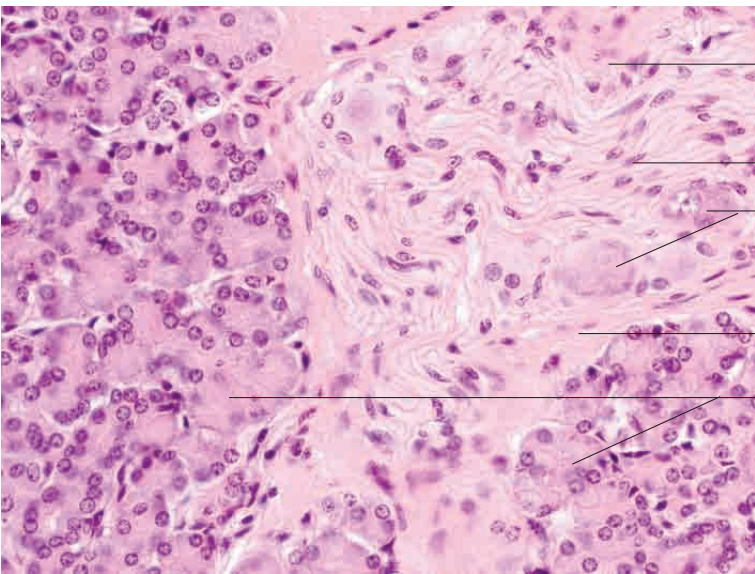
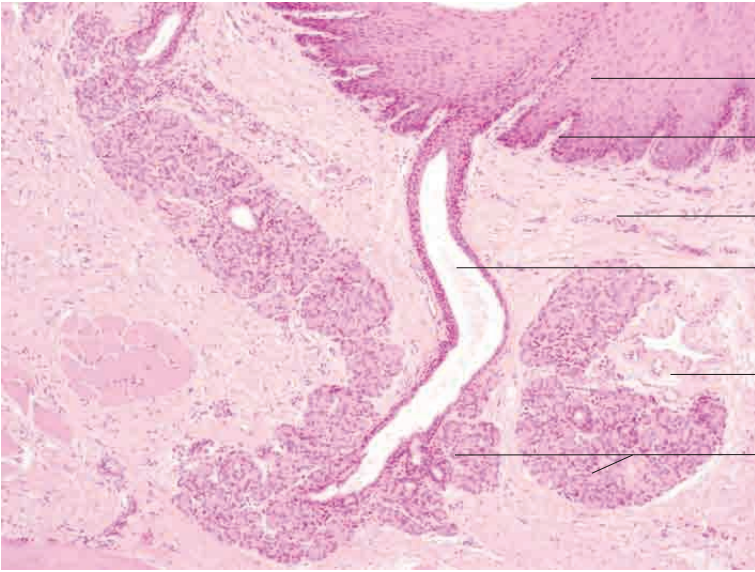
Actively secreting mixed glands

Inactive mixed glands

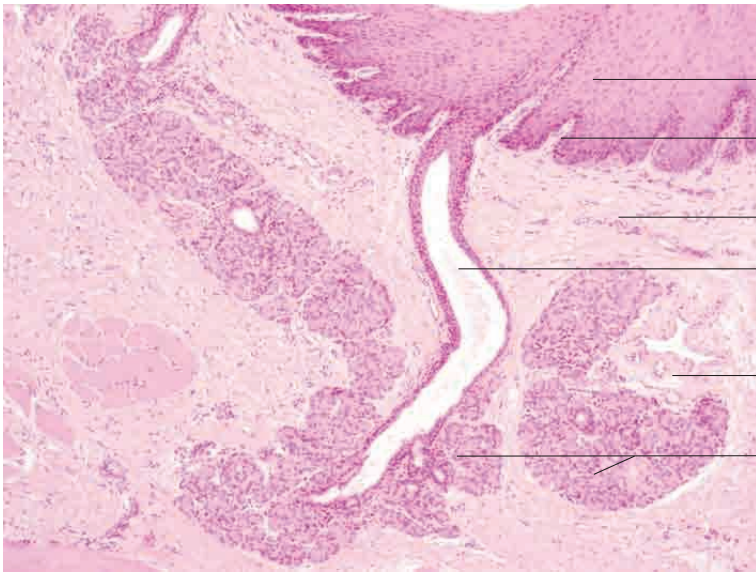
Lingual glands, cat. Mucicarmine stain; x200.

# 10 Digestive system

---







Stratified squamous epithelium

Papillary body

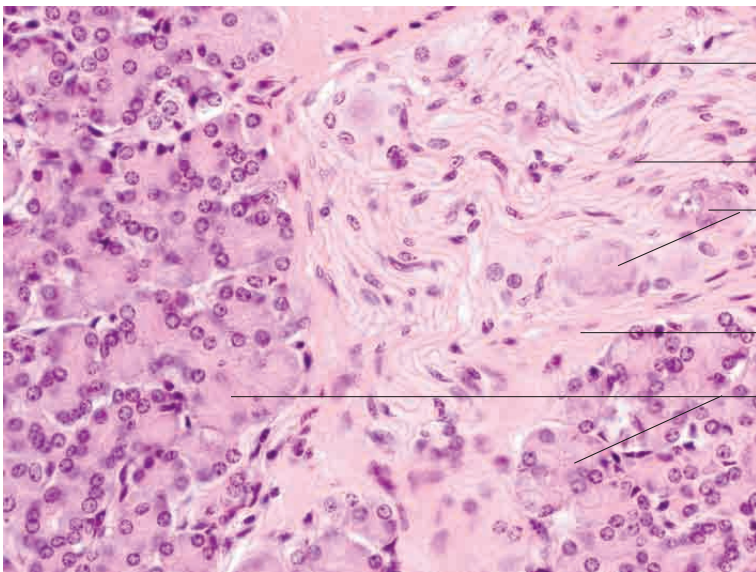
Lamina propria mucosae

Gland duct

Tela submucosa

Accumulation of serous glands

Base of tongue, horse. H.E. stain; x120.



Loose perineural connective tissue

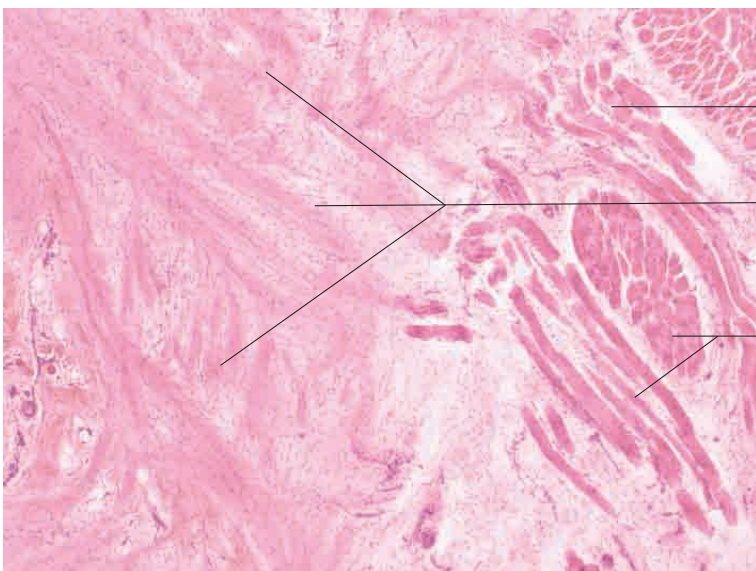
Nerve fibre bundle

Nuclei of multipolar nerve cells

Loose perineural connective tissue

Serous glands in tela submucosa

Base of tongue, horse. H.E. stain; x400.



Striated intrinsic muscle of tongue

Dense collagen fibre bundles with hyaline ground substance forming structural basis of dorsal lingual cartilage

Striated intrinsic muscle of tongue

Dorsal lingual cartilage, horse. H.E. stain; x40.