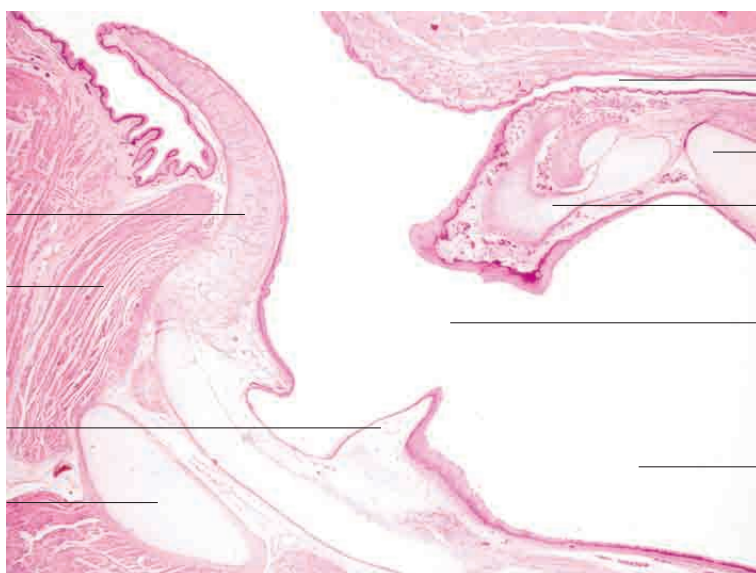
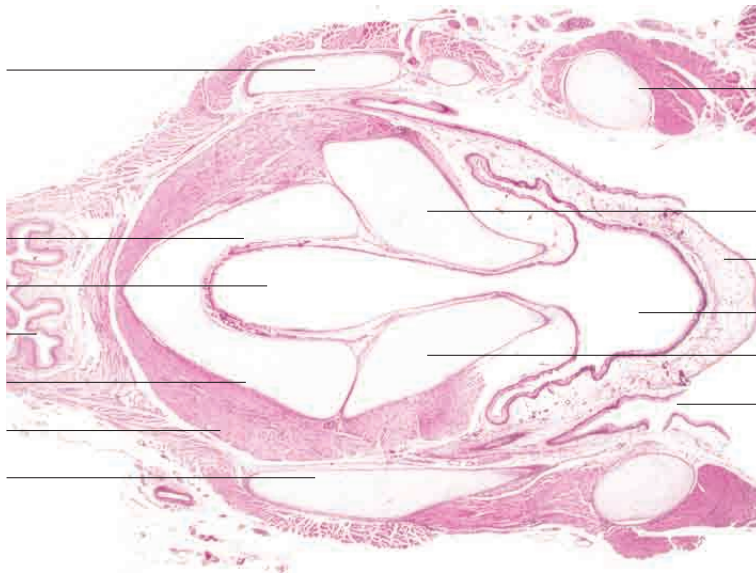
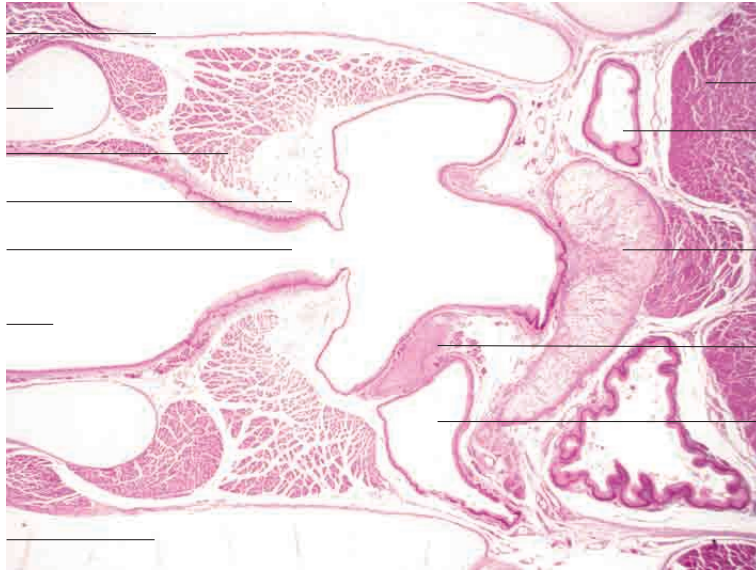
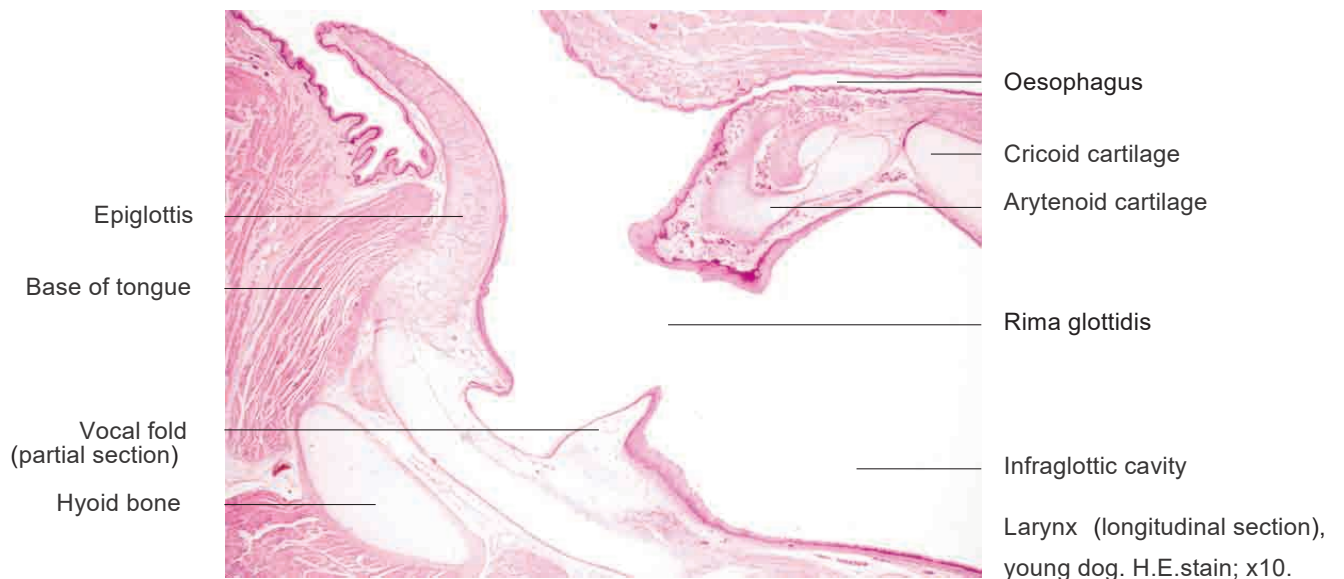
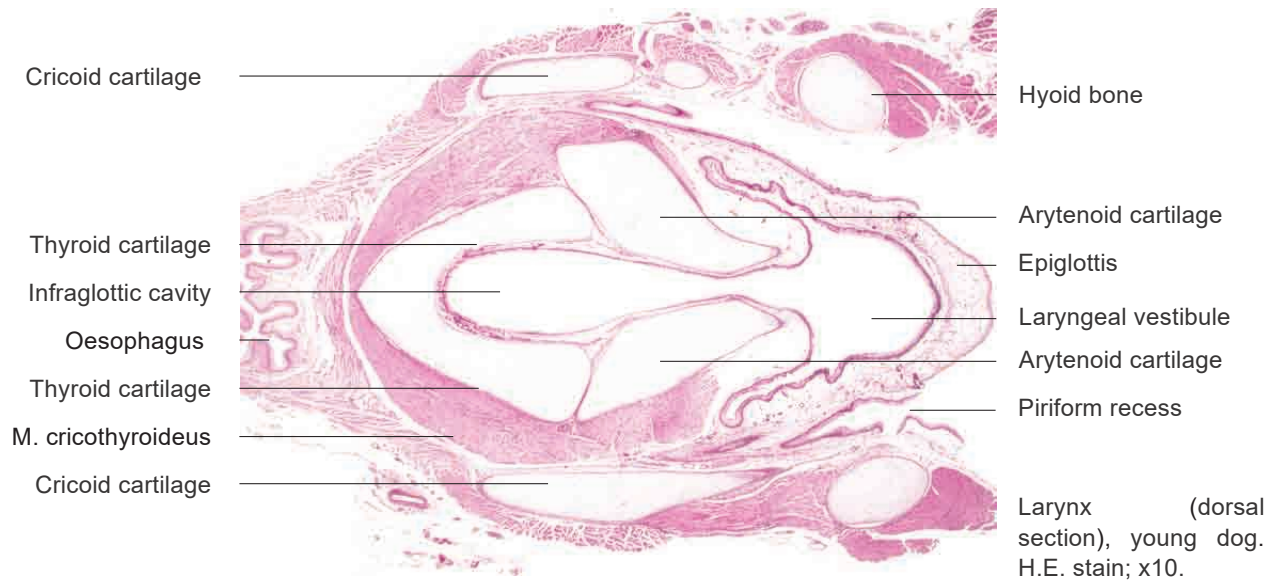
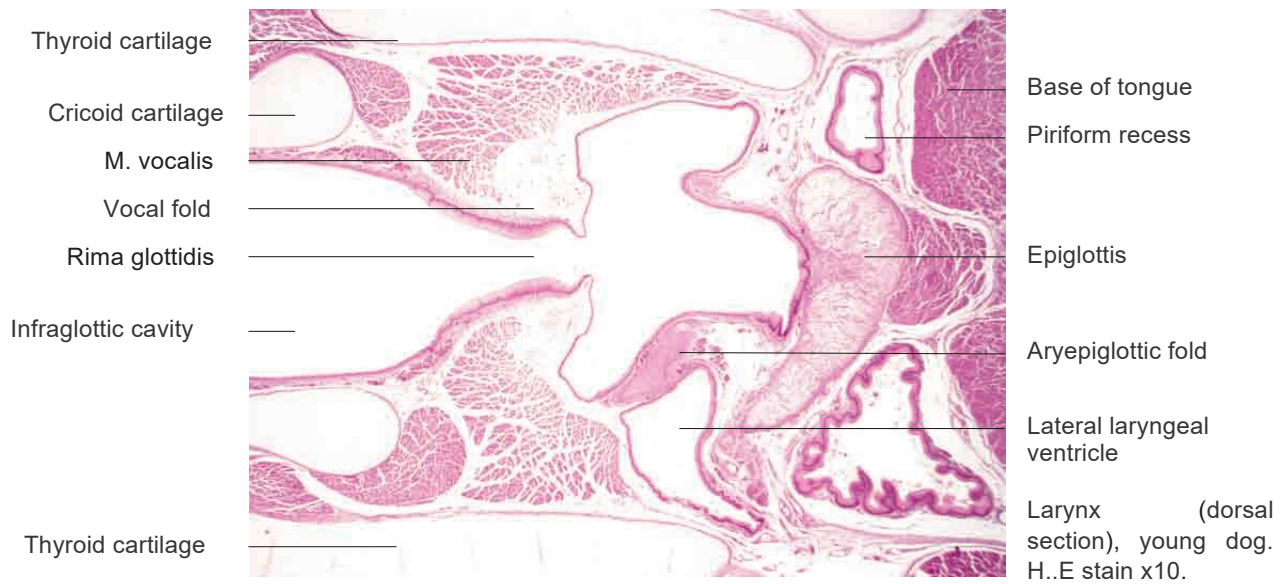


# 11 Respiratory system

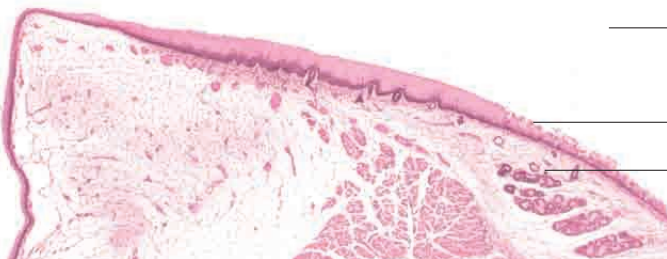
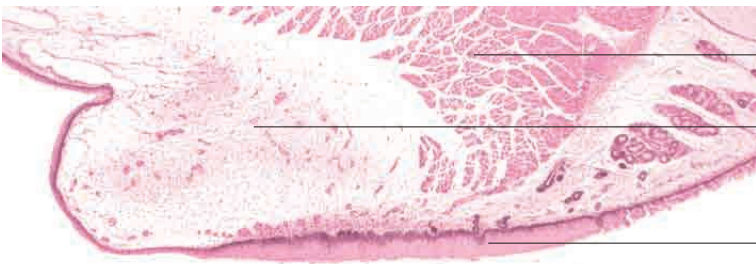
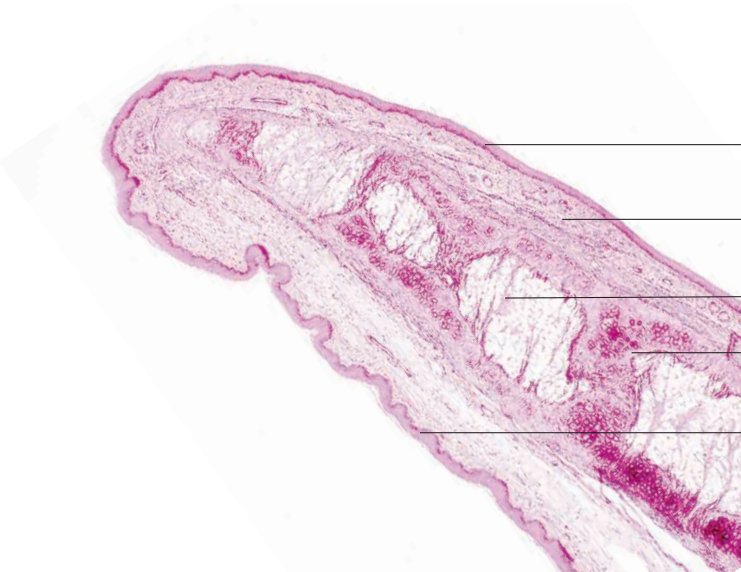
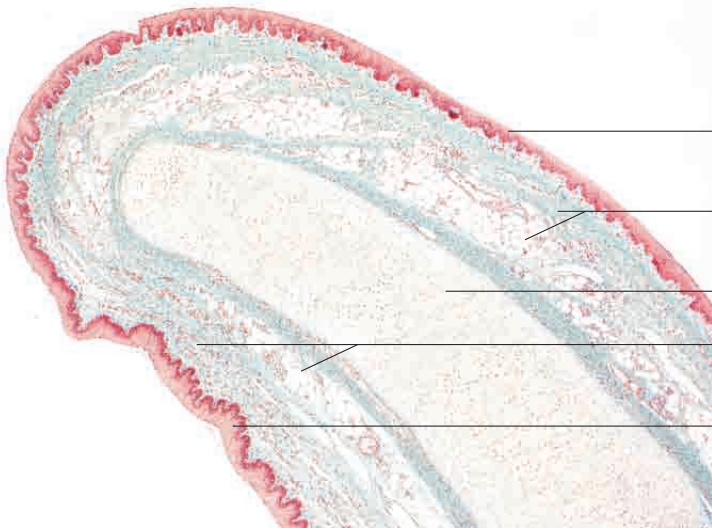
---

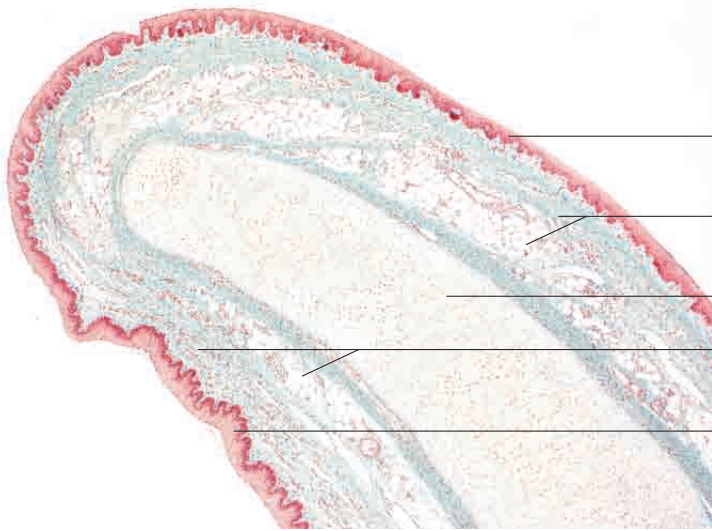




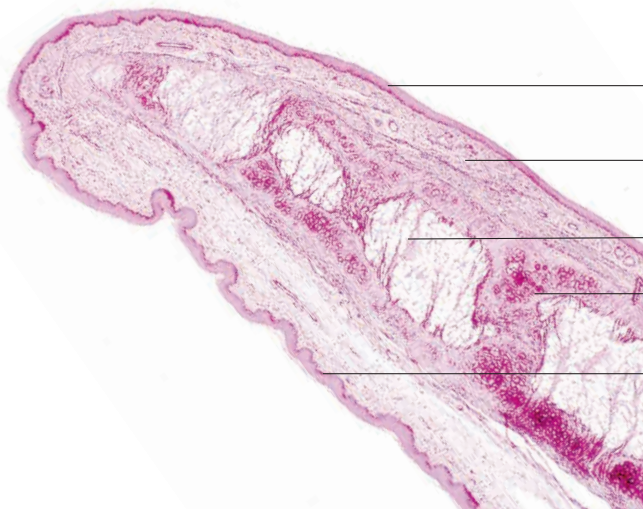
# 11 Respiratory system

---

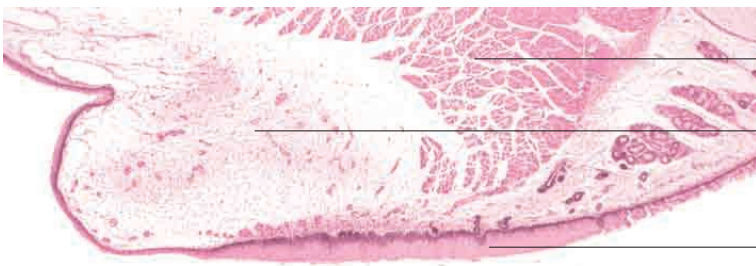




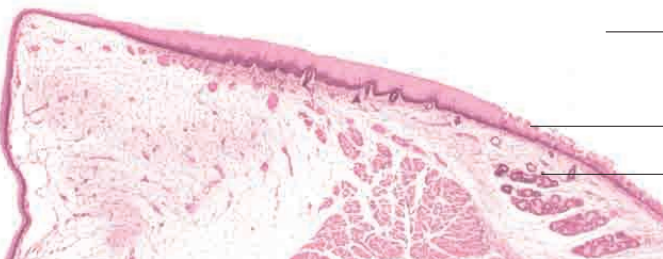
Stratified squamous epithelium (laryngeal surface)  
 Loose connective tissue with mucous glands  
 Laryngeal cartilage (elastic)  
 Loose connective tissue with mucous glands  
 Stratified squamous epithelium (lingual surface)  
 Epiglottis, pig. Goldner's Masson trichrome stain; x40.



Stratified squamous epithelium (laryngeal surface)  
 Loose connective tissue with elastic fibres and isolated mucous glands  
 Unilocular (white) adipose tissue  
 Laryngeal cartilage (elastic)  
 Stratified squamous epithelium (lingual surface)  
 Epiglottis, dog. Elastic stain; x40.



M. vocalis  
 Vocal fold  
 Stratified squamous epithelium



Beginning of tracheal lumen  
 Transition to respiratory mucosa  
 Tracheal glands  
 Larynx at level of vocal folds, young dog. H.E. stain; x40.