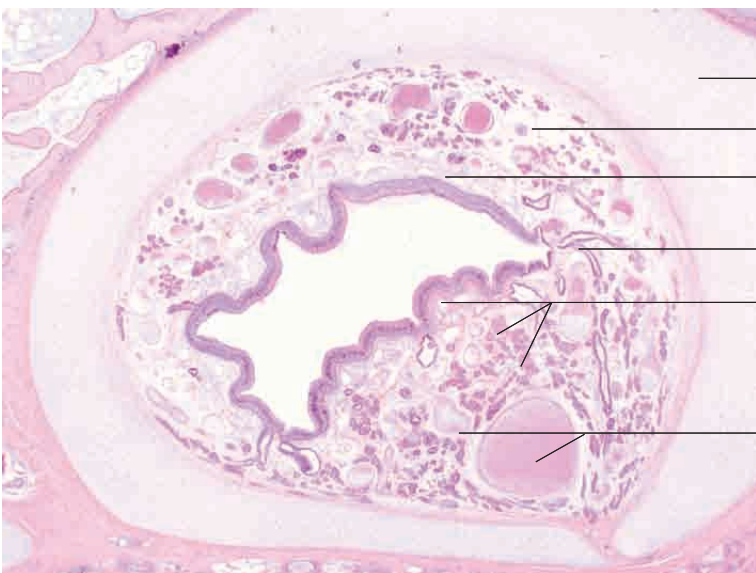
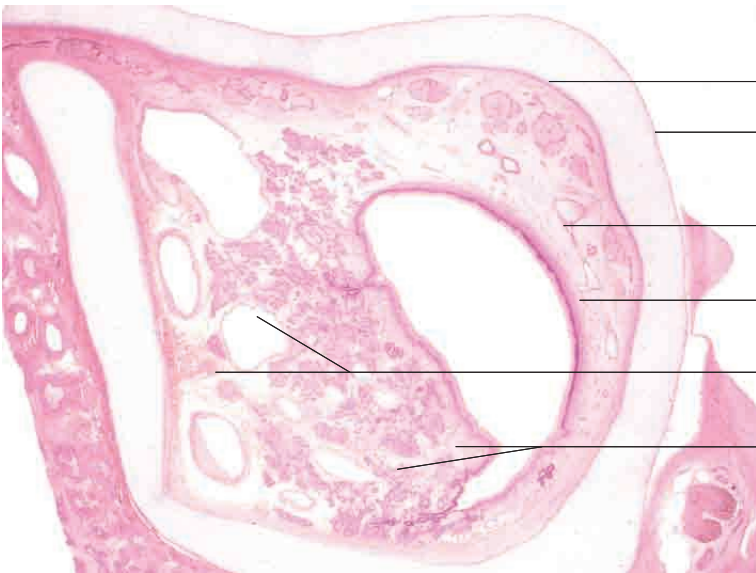
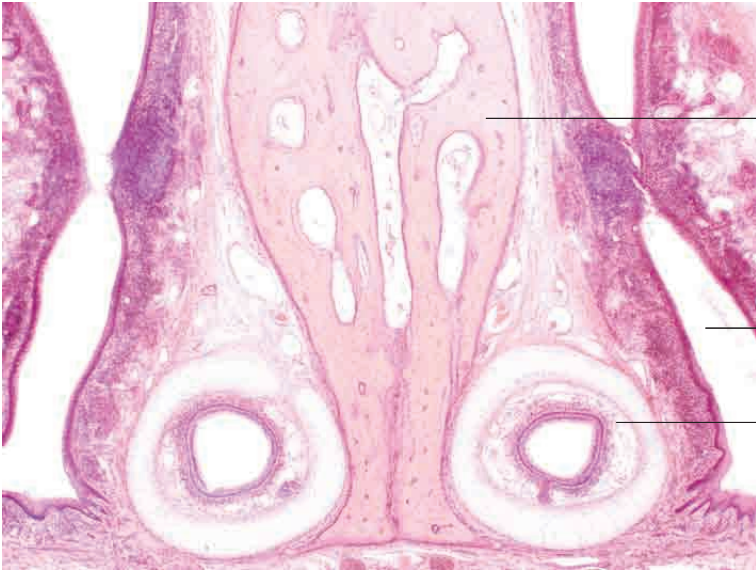
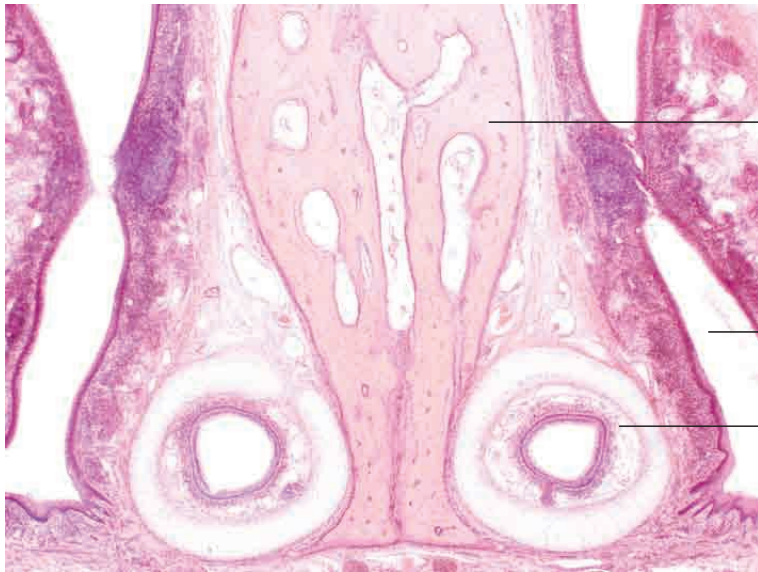# 11 Respiratory system

---



## Vomeronasal organ

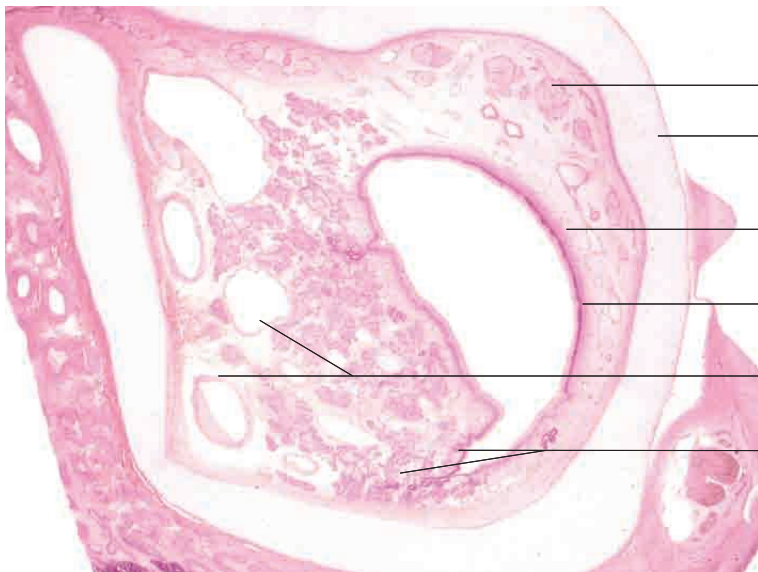

Vomer

Ventral nasal meatus

Vomeronasal organ

Vomeronasal organ, cat. H.E stain; x30.



Nerve fibre bundle (cross section)

Hyaline supportive cartilage

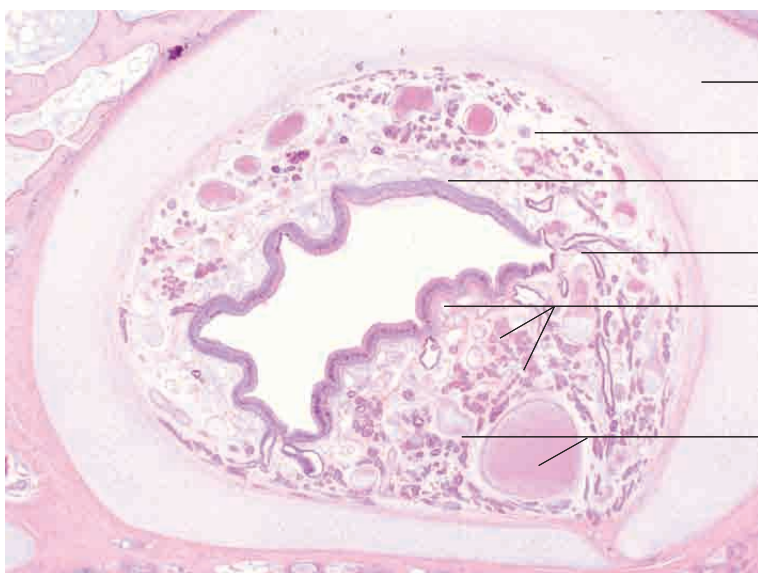Olfactory mucosa

Olfactory epithelium

Capacitance veins

Respiratory mucosa with underlying serous glands

Vomeronasal organ, calf. H.E, stain; x40.



Hyaline supportive cartilage

Nerve fibre bundle (cross section)

Olfactory mucosa with vascular plexus

Secretory ducts

Respiratory mucosa with underlying serous glands

Capacitance veins

Vomeronasal organ, goat. H.E. stain; x40.