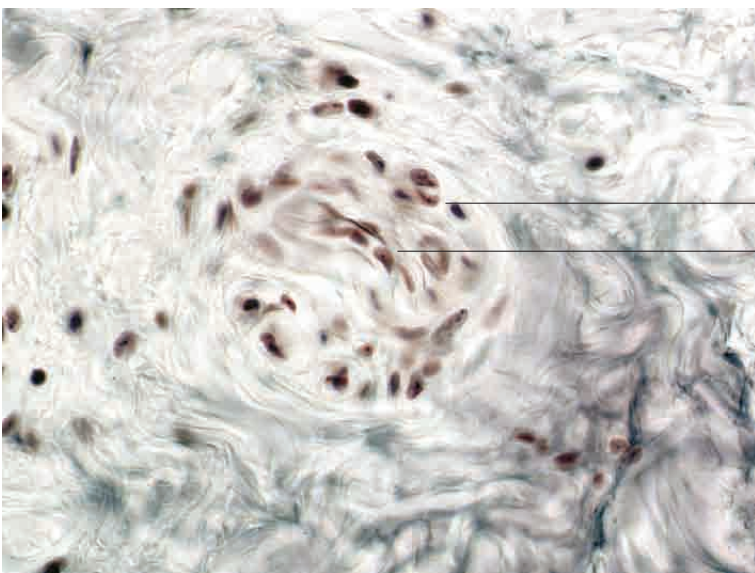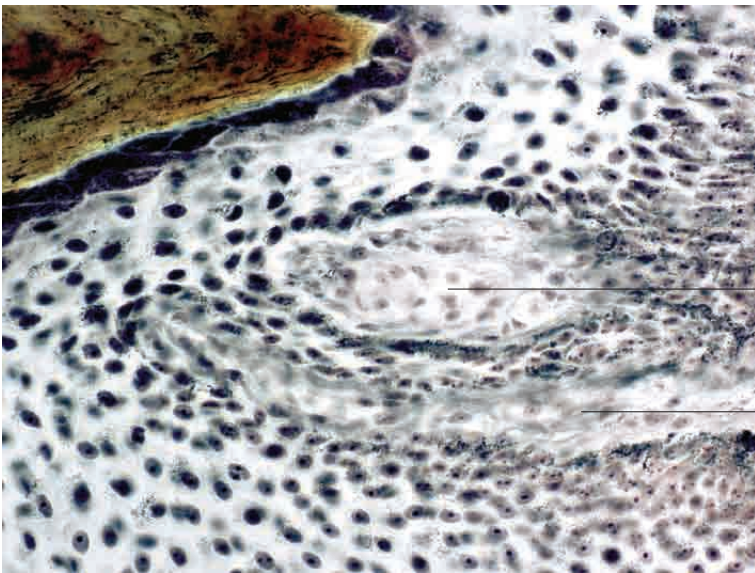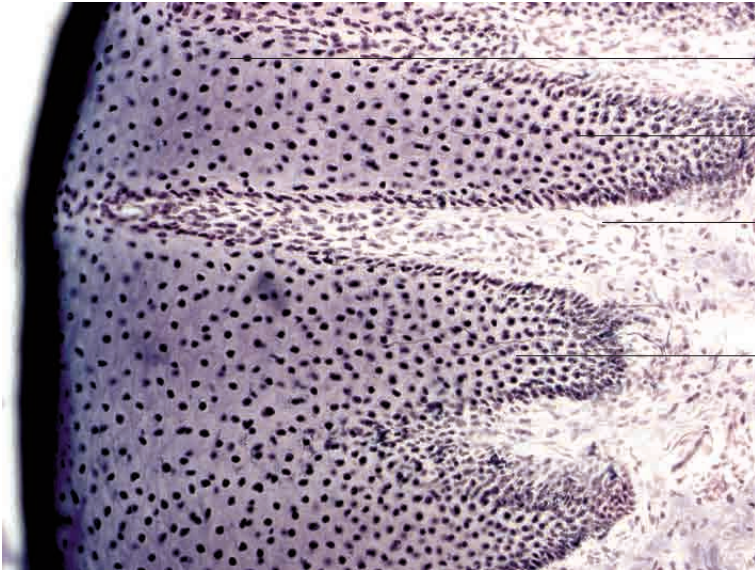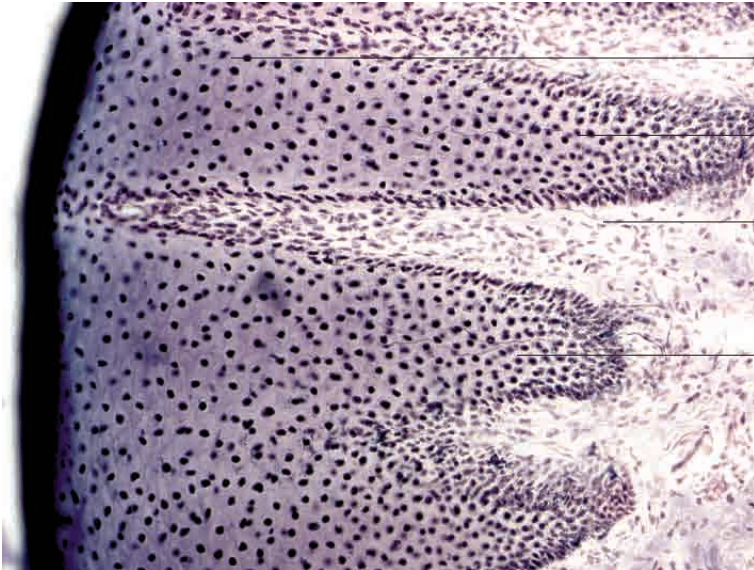


Exteroreceptors



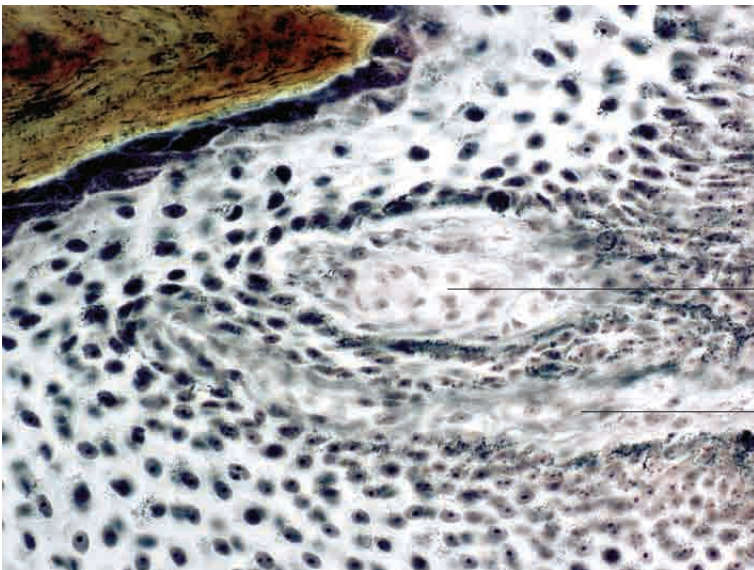
Epidermis, stratified squamous epithelium (nasolabial plate)

Intra-epithelial free nerve endings (unmyelinated)

Nerve fibre (myelinated) in loose connective tissue

Intraepithelial free nerve endings (unmyelinated)

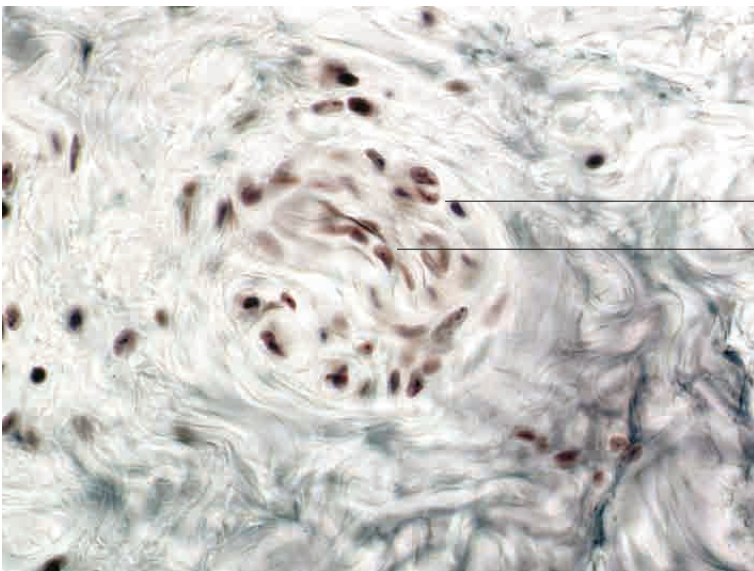
Free nerve endings, nasolabial plate, ox. Preparation according to Scheffthaler-Mayet; x280.



Meissner's corpuscles with nerve fibres

Loose connective tissue in lamina propria mucosae

Simple receptors, nasolabial plate, ox. Preparation according to Scheffthaler-Mayet; x400.



Connective tissue capsule

Ruffini's corpuscle

Simple receptors, subcutis, ox. Preparation according to Scheffthaler-Mayet; x400.